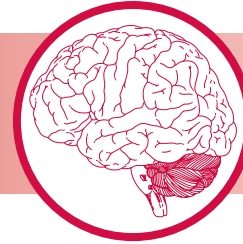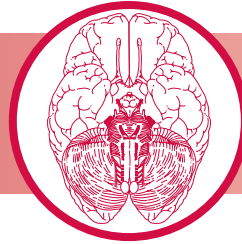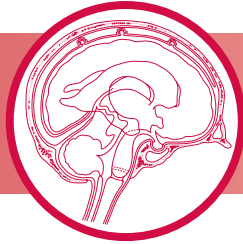


CHAPTER 10



Ascending Sensory Pathways

CLINICAL CASE

SENSORY RECEPTORS

ANTEROLATERAL SYSTEM

TACTILE SENSATION AND PROPRIOCEPTION

SENSORY PATHWAYS TO THE CEREBELLUM

CLINICAL CONSIDERATIONS

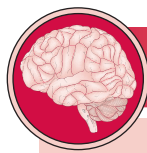MODULATION OF NOCICEPTION

NEUROPLASTICITY

SYNONYMS AND EPONYMS

FOLLOW-UP TO CLINICAL CASE

QUESTIONS TO PONDER



CLINICAL CASE

A 60-year-old woman complains of falls, imbalance, and numbness and tingling in her hands and legs. There is also some incoordination of hand use and she has difficulty manipulating small items such as buttons. She is unable to play the piano now since she cannot position her fingers correctly on the piano keys. She thinks the strength in her arms and legs is adequate. Symptoms started with very slight tingling sensations, which she noticed about 5 years ago. The falls and difficulty walking have been present for about 2 months. Higher order cognitive functions are intact according to her husband. Her vision is

normal.

On examination, the patient shows normal mental status. Strength seems essentially normal throughout. Sensation, particularly to vibration and joint position, is severely diminished in the distal upper and lower limbs (arms, legs, hands, and feet). Tendon reflexes are normal in the arms, but somewhat brisk in the legs at the knees and ankles. Gait is moderately ataxic and she has to reach out for support by touching the walls of the hallway at times. Fine movements of the fingers are performed poorly, even though finger and wrist strength seems normal.

A variety of **sensory receptors** scattered throughout the body can become activated by exteroceptive, interoceptive, or proprioceptive input. Exteroceptive input relays sensory information about the body's interaction with the external environment. Interoceptive input relays information about the body's internal state, whereas proprioceptive input conveys information about position sense from the body and its component parts. Each receptor is specialized to detect mechanical, chemical, nociceptive (L. *nocere*, "to injure," "painful"), or thermal stimuli. Activation of a sensory receptor is converted into nerve impulses and this sensory input is then conveyed via the fibers of the cranial or spinal nerves to their respective relay nuclei in the central nervous system (CNS). The sensory information is then further processed as it

progresses, via the **ascending sensory systems (pathways)**, to the cerebral cortex or to the cerebellum. Sensory information is also relayed to other parts of the CNS where it may function to elicit a reflex response, or may be integrated into pattern-generating circuitry.

The ascending sensory pathways are classified according to the functional components (modalities) they carry as well as by their anatomical localization. The two functional categories are the **general somatic afferent (GSA) system**, which transmits sensory information such as touch, pressure, vibration, pain, temperature, stretch, and position sense from **somatic** structures; and the **general visceral afferent (GVA) system**, which transmits sensory information such as pressure, pain, and other visceral sensation from **visceral** structures.

Anatomical system	Anatomical tracts	Functional component(s)
Anterolateral (ALS)	Spinothalamic* Spinoreticular Spinomesencephalic Spinotectal Spinohypothalamic	Pain, temperature, nondiscriminative (crude) touch, pressure, and some proprioceptive sensation
Dorsal column–medial lemniscal (DCML)*	Fasciculus gracilis Fasciculus cuneatus	Discriminative (fine) touch, vibratory sense, position sense
Somatosensory to the cerebellum	Anterior spinocerebellar Posterior spinocerebellar Rostral spinocerebellar Cuneocerebellar	Primarily proprioceptive information (also some pain and pressure information)

*Indicates conscious level.

Table 10.1 ● A general description of the anatomical and functional aspects of the ascending sensory pathways.

Anatomically, the ascending sensory systems consist of three distinct pathways: the anterolateral system (ALS), the dorsal column–medial lemniscal (DCML) pathway, and the somatosensory pathways to the cerebellum.

The **anterolateral system**, which includes the **spinothalamic**, **spinoreticular**, **spinomesencephalic**, **spinotectal**, and **spinohypothalamic tracts**, relays predominantly pain and temperature sensation, as well as nondiscriminative (crude or poorly localized) touch, pressure, and some proprioceptive sensation (Table 10.1).

The **dorsal column–medial lemniscal pathway** (which includes the **fasciculus gracilis**, **fasciculus cuneatus**, and **medial lemniscus**) relays discriminative (fine) tactile sense, vibratory sense, and position sense (Table 10.1).

The **somatosensory pathways to the cerebellum**, which include the **anterior**, **posterior**, and **rostral spinocerebellar**, as well as the **cuneocerebellar tracts**, relay primarily proprioceptive (but also some pain and pressure) information (Table 10.1).

The ascending sensory pathways are the main avenues by which information concerning the body's interaction with the external environment, its internal condition, and the position and movement of its parts, reach the brain. One similarity shared by all three ascending sensory pathways from the body (not including the head or face) is that the first order neuron cell bodies reside in the **dorsal root ganglia**. It is interesting to note that **conscious perception** of sensory information from external stimuli is mediated by the **spinothalamic** and **DCML pathways** to the ventral posterior lateral nucleus of the **thalamus**, whereas sensations that do *not* reach consciousness are mediated by the **spinoreticular**, **spinomesencephalic**, **spinotectal**, **spinohypothalamic**, and the **anterior**, **posterior**, and **rostral spinocerebellar**, and **cuneocerebellar tracts**. These tracts terminate in the reticular formation, mesencephalon, hypothalamus and cerebellum, respectively.

Sensory input may ultimately elicit a reflex or other motor response because of the functional integration of the

ascending (somatosensory) pathways, the cerebellum, and the somatosensory cortex, as well as the motor cortex and descending (motor) pathways. Furthermore, descending projections from the **somatosensory cortex**, as well as from the **raphe nucleus magnus** and the **dorsolateral pontine reticular formation** to the **somatosensory relay nuclei** of the brainstem and spinal cord, modulate the transmission of incoming sensory impulses to higher brain centers.

This chapter includes a description of the sensory receptors and the ascending sensory pathways from the body, whereas the ascending sensory pathways from the head, transmitted mostly by the trigeminal system, are described in Chapter 15.

SENSORY RECEPTORS

Although sensory receptors vary, they generally all function in a similar fashion

Although sensory receptors vary according to their morphology, the velocity of conduction, and the modality to

which they respond, as well as to their location in the body, they generally all function in a similar fashion. The stimulus to which a specific receptor responds causes an alteration in the ionic permeability of the nerve endings, generating a **receptor potential** that results in the formation of **action potentials**. This transformation of the stimulus into an electrical signal is referred to as **sensory transduction**.

Some receptors that respond quickly and maximally at the onset of the stimulus, but stop responding even if the stimulus continues, are known as **rapidly adapting (phasic) receptors**. These are essential in responding to changes but they ignore ongoing processes, such as when one wears a wristwatch and ignores the continuous pressure on the skin of the wrist. However, there are other receptors, **slowly adapting (tonic) receptors**, that continue to respond as long as the stimulus is present.

Sensory receptors are classified according to the **source of the stimulus** or according to the **modality** to which they

respond. It is important to note that, in general, receptors do not transmit only one specific sensation.

Classification according to stimulus source

Receptors that are classified according to the source of the stimulus are placed in one of the following three categories: exteroceptors, proprioceptors, or interoceptors.

Exteroceptors are close to the body surface and are specialized to detect sensory information from the external environment

1 **Exteroceptors** are close to the body surface and are specialized to detect sensory information from the external environment (such as visual, olfactory, gustatory, auditory, and tactile stimuli). Receptors in this class are sensitive to touch (light stimulation of the skin surface), pressure (stimulation of receptors in the deep layers of the skin, or deeper parts of the body), temperature, pain, and vibration. Exteroceptors are further classified as teloreceptors or contact receptors:

- **teloreceptors** (G. tele, “distant”), include receptors that respond to distant stimuli (such as light or sound), and do not require direct physical contact with the stimulus in order to be stimulated;
- **contact receptors**, which transmit tactile, pressure, pain, or thermal stimuli, require direct contact of the stimulus with the body.

Proprioceptors transmit sensory information from muscles, tendons, and joints about the position of a body part, such as a limb in space

2 **Proprioceptors** transmit sensory information from muscles, tendons, and joints about the position of a body part, such as a limb in space. There is a *static* position sense relating to a stationary position and a *kinesthetic* sense (G. kinesis, “movement”), relating to the movement of a body part. The receptors of the vestibular system located in the inner ear, relaying sensory information about the movement and orientation of the head, are also classified as proprioceptors.

Interoceptors detect sensory information concerning the status of the body's internal environment

3 **Interoceptors** detect sensory information concerning the status of the body's internal environment, such as stretch, blood pressure, pH, oxygen or carbon dioxide concentration, and osmolarity.

Classification according to modality

Receptors are further classified into the following three categories according to the modality to which they respond: nociceptors, thermoreceptors, and mechanoreceptors (Table 10.2).

Nociceptors

Nociceptors are rapidly adapting receptors that are sensitive to noxious or painful stimuli

Nociceptors are rapidly adapting receptors that are sensitive to noxious or painful stimuli. They are located at the peripheral terminations of lightly myelinated free nerve endings of **type A δ fibers**, or unmyelinated **type C fibers**, transmitting pain. Nociceptors are further classified into three types.

- 1 **Mechanosensitive nociceptors** (of A δ fibers), which are sensitive to intense mechanical stimulation (such as pinching with pliers) or injury to tissues.
- 2 **Temperature-sensitive (thermosensitive) nociceptors** (of A δ fibers), which are sensitive to intense heat and cold.
- 3 **Polymodal nociceptors** (of C fibers), which are sensitive to noxious stimuli that are mechanical, thermal, or chemical in nature. Although most nociceptors are sensitive to one particular type of painful stimulus, some may respond to two or more types.

Nociception is the reception of noxious sensory information elicited by tissue injury, which is transmitted to the CNS by nociceptors. **Pain** is the perception of discomfort or an agonizing sensation of variable magnitude, evoked by the stimulation of sensory nerve endings.

Thermoreceptors

Thermoreceptors are sensitive to warmth or cold

Thermoreceptors are sensitive to warmth or cold. These slowly adapting receptors are further classified into three types.

- 1 **Cold receptors**, which consist of free nerve endings of lightly myelinated A δ fibers.
- 2 **Warmth receptors**, which consist of the free nerve endings of unmyelinated C fibers that respond to *increases* in temperature.
- 3 **Temperature-sensitive nociceptors** that are sensitive to excessive heat or cold.

Mechanoreceptors

Mechanoreceptors are activated following physical deformation of the skin, muscles, tendons, ligaments, and joint capsules in which they reside

Mechanoreceptors, which comprise both exteroceptors and proprioceptors, are activated following physical deformation due to touch, pressure, stretch, or vibration of the skin, muscles, tendons, ligaments, and joint capsules, in which they reside. A mechanoreceptor may be classified as **nonencapsulated** or **encapsulated** depending on whether a structural device encloses its peripheral nerve ending component.

Table 10.2 ● Sensory receptors.

Sensory receptors	Mediate/respond to	Endings	Location	Associated with	Pathways	Rate of adaptation
Nociceptors						
Pain	Tissue damage	Branching free nerve (A δ , C) endings (unmyelinated nonencapsulated)	Epidermis, dermis, cornea, muscle, joint capsules	A δ (group III) myelinated fibers, C (group IV) unmyelinated fibers	Anterolateral system	Slow
Temperature	Extreme temperature					
Mechanoreceptors						
Free nerve endings	Touch, pressure	Nonencapsulated	Epidermis, dermis, cornea, dental pulp, muscle, tendons, ligaments, joint capsules, bones, mucous membranes	A δ , C fibers	Anterolateral system	Slow
Merkel's tactile discs	Discriminative touch, superficial pressure	Nonencapsulated	Basal epidermis	A β (group II) myelinated fibers	DCML pathway	Slow
Meissner's corpuscles	Two-point discriminative (fine) touch	Encapsulated	Papillae of dermis of hairless skin	A β (group II) myelinated fibers	DCML pathway	Rapid
Pacinian corpuscles	Deep pressure and vibratory sensation	Encapsulated	Dermis, hypodermis, interosseous membranes, ligaments, external genitalia, joint capsules, peritoneum, pancreas	A β (group II) myelinated fibers	DCML pathway	Rapid
Peritrichial nerve endings	Touch, hair movement (bending)	Nonencapsulated	Around hair follicle	A β (group II) myelinated fibers	DCML pathway	Rapid
Ruffini's organs	Pressure on, or stretching of, skin	Encapsulated	Joint capsules, dermis, hypodermis	A β (group II) myelinated fibers	DCML pathway	Slow
Muscle and tendon mechanoreceptors						
Nuclear bag fibers	Detects onset of muscle stretch		Skeletal muscle	A α (group Ia) myelinated fibers	DCML pathway and ascending sensory pathways to the cerebellum	Both slow and rapid
Nuclear chain fibers	Muscle stretch in progress		Skeletal muscle	also secondary afferents, muscle spindle afferents		
Golgi tendon organs	Stretching of tendon		Skeletal muscle	A α (group Ib) myelinated fibers		Slow

DCML, dorsal column–medial lemniscal.

Nonencapsulated mechanoreceptors

Nonencapsulated mechanoreceptors are slowly adapting and include free nerve endings and tactile receptors

Free nerve endings (Fig. 10.1) are present in the epidermis, dermis, cornea, dental pulp, mucous membranes of the oral and nasal cavities and of the respiratory, gastrointestinal, and urinary tracts, muscles, tendons, ligaments, joint capsules, and bones. The peripheral nerve terminals of the free nerve endings lack Schwann cells and myelin sheaths. They are stimulated by touch, pressure, thermal, or painful stimuli.

Peritrichial nerve endings (Fig. 10.2) are specialized members of this category. They are large-diameter, myelinated, A β fibers that coil around a hair follicle below its associated sebaceous gland. This type of receptor is stimulated only when a hair is being bent.

Tactile receptors (Fig. 10.3) consist of disc-shaped, peripheral nerve endings of large-diameter, myelinated, A β fibers. Each disc-shaped terminal is associated with a specialized epithelial cell, the Merkel cell, located in the stratum basale of the epidermis. These receptors, frequently referred to as **Merkel's discs** (Fig. 10.4), are present mostly in glabrous (hairless), and occasionally in hairy skin. Merkel's discs

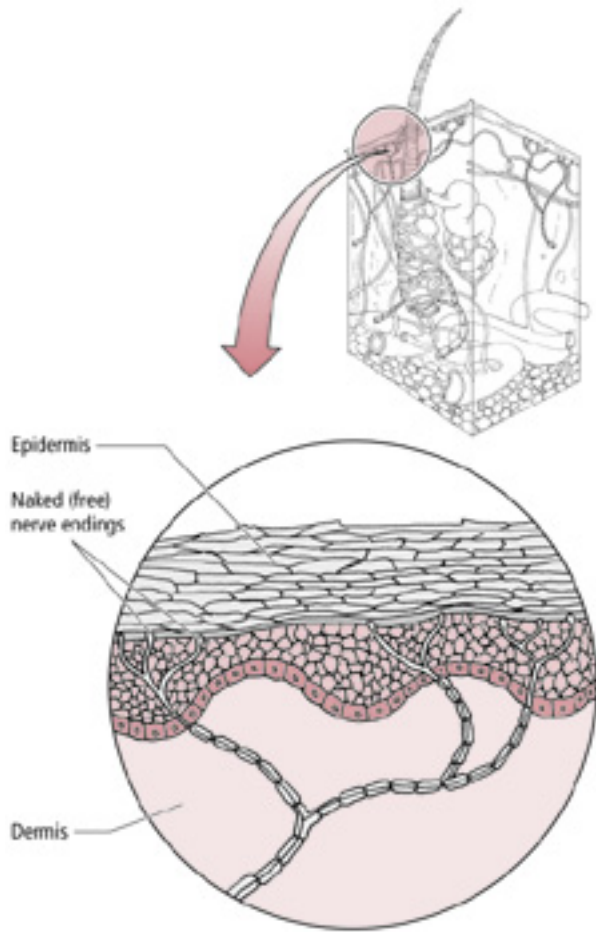


Figure 10.1 ● Free nerve endings in the skin. The free nerve endings terminating in the epidermis lose their myelin sheath. Many free nerve endings have unmyelinated axons.

respond to discriminative touch stimuli that facilitate the distinguishing of texture, shape, and edges of objects.

Encapsulated mechanoreceptors

Encapsulated mechanoreceptors include Meissner’s corpuscles, pacinian corpuscles, and Ruffini’s end organs.

Meissner’s corpuscles are present in the dermal papillae of glabrous skin of the lips, forearm, palm, and sole, and in the connective tissue papillae of the tongue

Meissner’s corpuscles (Fig. 10.5) are present in the dermal papillae of glabrous skin of the lips, forearm, palm, and sole, as well as in the connective tissue papillae of the tongue. These corpuscles consist of the peripheral terminals of Aβ fibers, which are encapsulated by a peanut-shaped structural device consisting of a stack of concentric Schwann cells surrounded by a connective tissue capsule. They are rapidly adapting and are sensitive to two-point tactile (fine) discrimination, and are thus of great importance to the visually impaired by permitting them to be able to read Braille.

Pacinian corpuscles are the largest of the mechanoreceptors

Pacinian corpuscles (Fig. 10.6), the largest of the mechanoreceptors, are rapidly adapting and resemble an onion in cross-section. Each Pacinian corpuscle consists of Aβ-fiber terminals encapsulated by layers of modified fibroblasts that are enclosed in a connective tissue capsule. Pacinian corpuscles are located in the dermis, hypodermis, interosseous membranes, ligaments, external genitalia, joint capsules, and peritoneum, as well as in the pancreas. They are more rapidly adapting than Meissner’s corpuscles and are believed to respond to pressure and vibratory stimuli, including tickling sensations.

Ruffini’s end organs are located in the joint capsules, dermis, and underlying hypodermis of hairy skin

Ruffini’s end organs (corpuscles of Ruffini) (Fig. 10.7) are located in joint capsules, the dermis, and the underlying hypodermis of hairy skin. The unmyelinated peripheral terminals of Aβ myelinated fibers are slowly adapting. They intertwine around the core of collagen fibers, which is surrounded by a lamellated cellular capsule. Ruffini’s end organs respond to *stretching* of the collagen bundles in the skin or joint capsules and may provide proprioceptive information.

Muscle spindles and **Golgi tendon organs** (GTOs) are also encapsulated mechanoreceptors, but, due to their specialized function, they are discussed separately.

Muscle spindles and Golgi tendon organs

Two types of proprioceptors, the neuromuscular (muscle) spindles and the GTOs (neurotendinous spindles), are associated with skeletal muscle only

The muscle spindles and GTOs detect sensory input from the skeletal muscle and transmit it to the spinal cord where it plays an important

role in reflex activity and motor control involving the cerebellum. In addition, sensory input from these muscle receptors is also relayed to the cerebral cortex by way of the DCML pathway, which mediates information concerning posture, position sense, as well as movement and orientation of the body and its parts.

Muscle spindles

Structure and function

Skeletal muscle consists of extrafusal and intrafusal fibers

Extrafusal fibers are ordinary skeletal muscle cells constituting the majority of gross muscle, and their stimulation results in muscle contraction. **Muscle spindles**, composed of small bundles of encapsulated **intrafusal fibers**, are dispersed throughout gross muscle. These are *dynamic stretch receptors* that continuously check for changes in muscle length.

Each muscle spindle is composed of two to 12 intrafusal fibers enclosed in a slender capsule, which in turn is

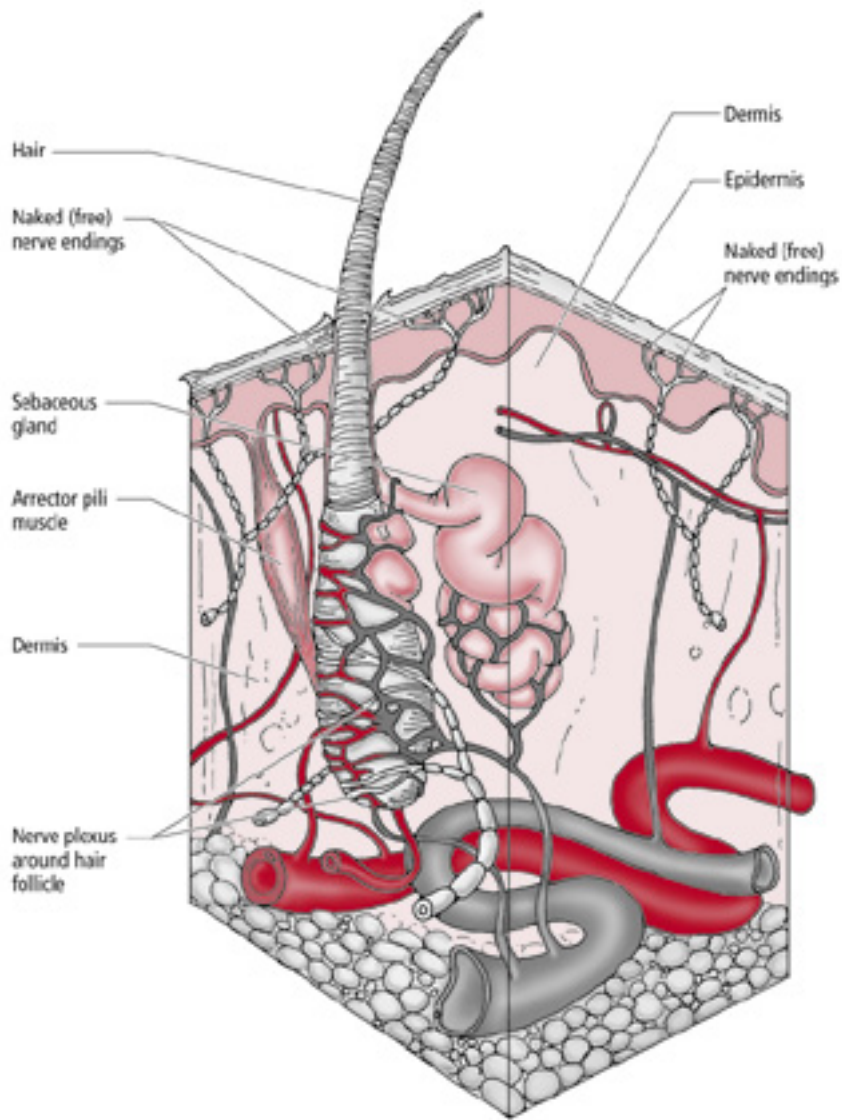


Figure 10.2 • Peritrichial nerve endings. These free nerve endings spiral around the base of a hair follicle.

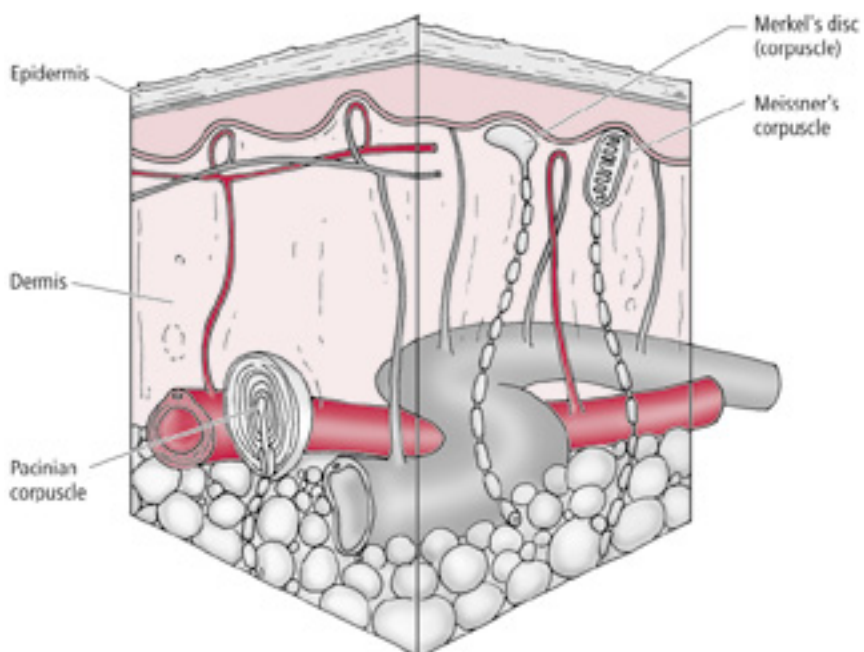


Figure 10.3 • A section of dermis showing a Merkel's disc, Meissner's corpuscle, and Pacinian corpuscle.

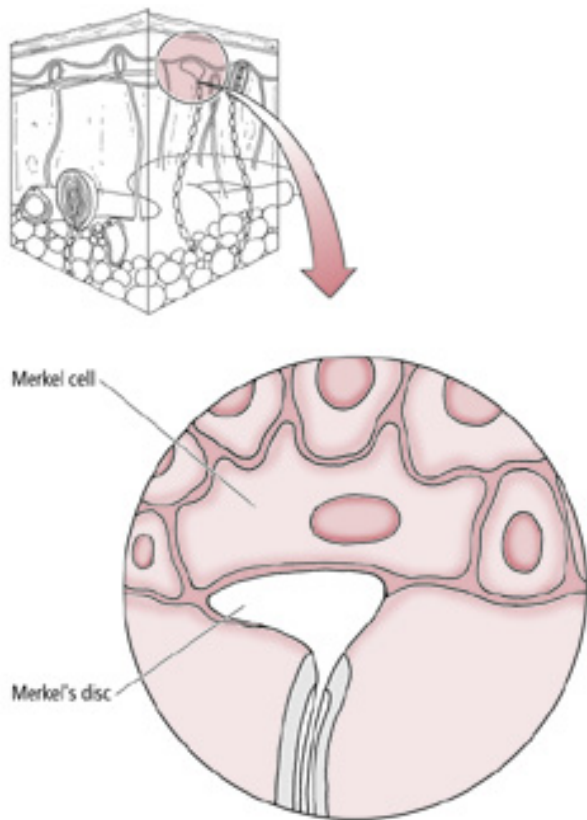


Figure 10.4 • Merkel's discs (corpuscles) terminate on the basal surface of the epidermis.

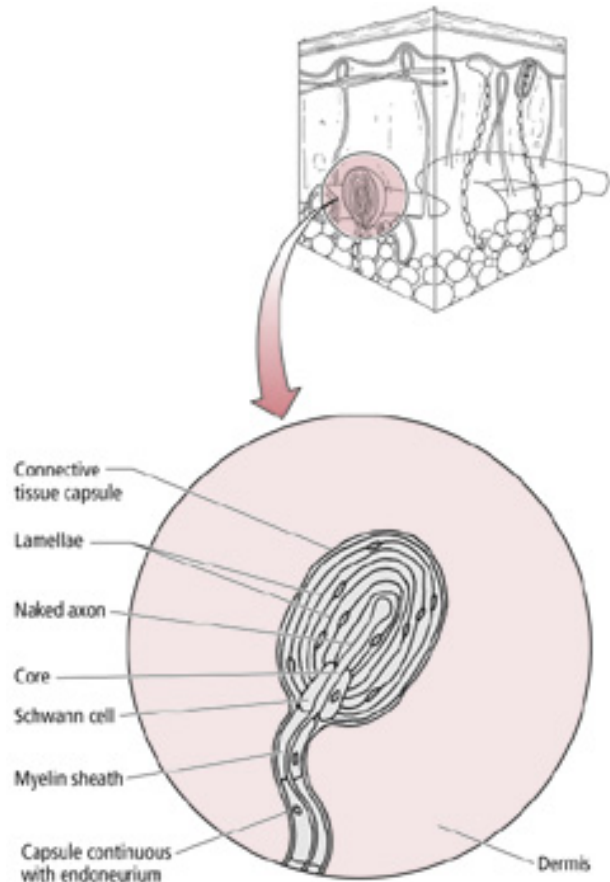


Figure 10.6 • Pacinian corpuscles are located in the dermis of the skin.

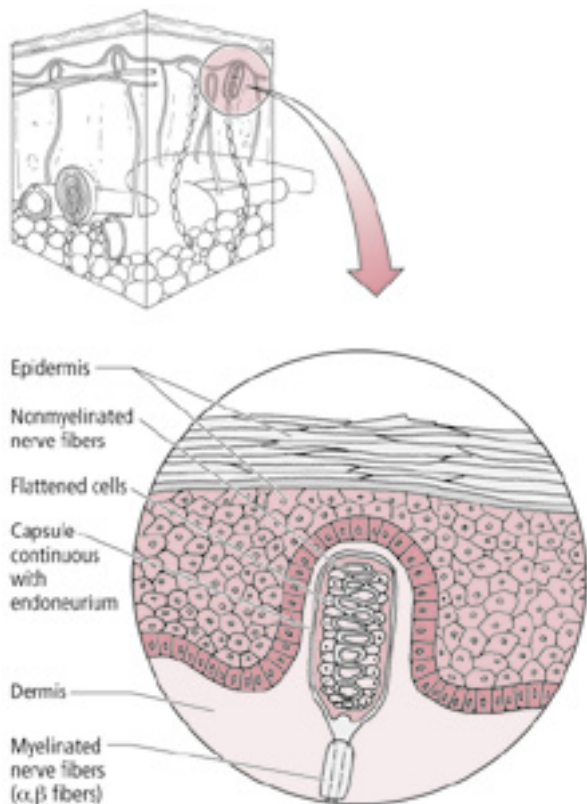


Figure 10.5 • Meissner's corpuscles are located in dermal papillae of the skin.

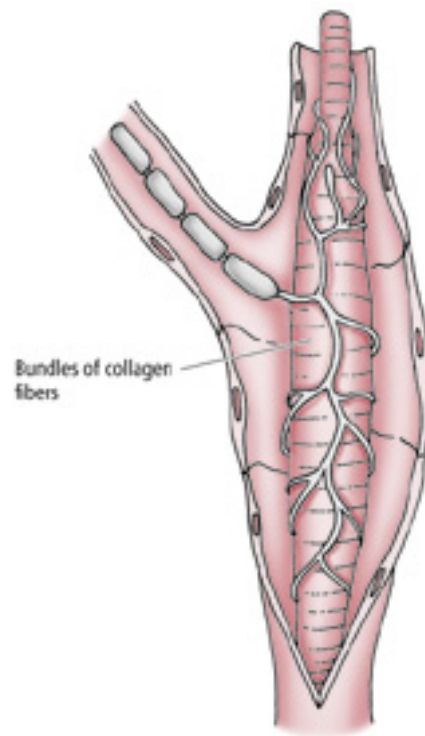


Figure 10.7 • A corpuscle of Ruffini.

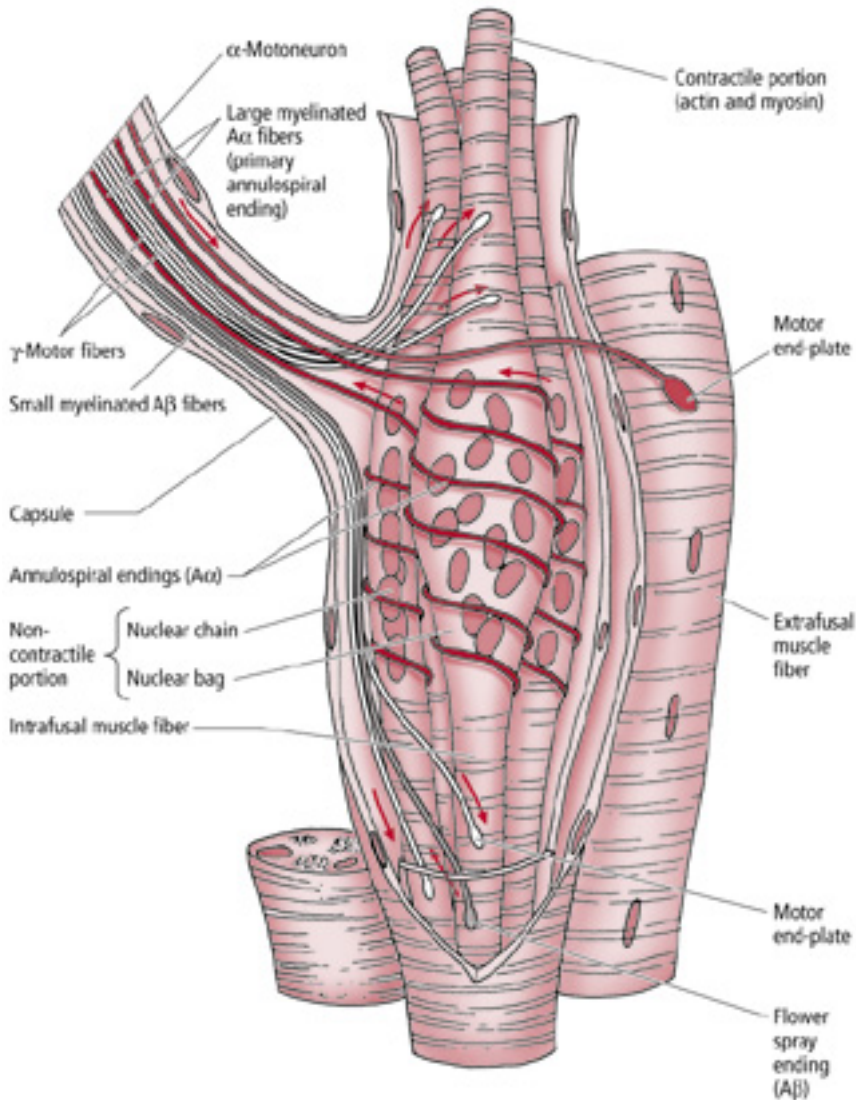


Figure 10.8 ● Right: an extrafusal skeletal muscle fiber. Left: a neuromuscular spindle containing the two types of intrafusal fibers—the nuclear bag fiber with multiple nuclei in the dilated central region and a nuclear chain fiber with a row of nuclei in its central region.

surrounded by an outer fusiform connective tissue capsule whose tapered ends are attached to the connective tissue sheath surrounding the extrafusal muscle fibers (Fig. 10.8). The compartment between the inner and outer capsules contains a glycosaminoglycan-rich viscous fluid.

There are two types of intrafusal fibers based on their morphological characteristics: nuclear bag fibers and nuclear chain fibers. Both nuclear bag and nuclear chain fibers possess a central, noncontractile region housing multiple nuclei, and a skeletal muscle (myofibril-containing) contractile portion at each end of the central region. The **nuclear bag fibers** are larger, and their multiple nuclei are clustered in the “bag-like” dilated central region of the fiber. The **nuclear chain fibers** are smaller and consist of multiple nuclei arranged sequentially, as in a “chain” of pearls, in the central region of the fiber.

Each intrafusal fiber of a muscle spindle receives sensory innervation via the peripheral processes of pseudounipolar sensory neurons whose cell bodies are housed in dorsal root ganglia, or in the sensory ganglia of the cranial nerves (and in the case of the trigeminal nerve, within its mesencephalic nucleus). Since the large-diameter $A\alpha$ fibers spiral around the noncontractile region of the intrafusal fibers, they are known as **annulospiral** or **primary** endings. These endings become activated at the **beginning of muscle stretch** or **tension**. In addition to the annulospiral endings, the intrafusal fibers, mainly the nuclear chain fibers, also receive smaller diameter, $A\beta$ peripheral processes of pseudounipolar neurons. These nerve fibers terminate on both sides of the annulospiral ending, are referred to as **secondary** or **flower spray endings**, and are activated during the time that the stretch is in progress (Fig. 10.8).

Each intrafusal fiber of a muscle spindle receives sensory innervation via the peripheral processes of pseudounipolar sensory neurons

In addition to sensory innervation, intrafusal fibers also receive motor innervation via gamma motoneurons that innervate the contractile portions of the intrafusal fibers, causing them to contract

In addition to the sensory innervation, intrafusal fibers also receive motor innervation via gamma motoneurons (fusimotor neurons) that innervate the contractile portions of the intrafusal fibers, causing them to undergo contraction. Since the intrafusal fibers are oriented parallel to the longitudinal axis of the extrafusal fibers, when a muscle is *stretched*, the central, noncontractile region of the intrafusal fibers is also stretched, distorting and stimulating the sensory nerve endings coiled around them, causing the nerve endings to fire. However, when the muscle *contracts*, tension on the central noncontractile region of the intrafusal fibers decreases (which reduces the rate of firing of the sensory nerve endings coiled around it).

During voluntary muscle activity simultaneous stimulation of the extrafusal fibers by the alpha motoneurons, and the contractile portions of the intrafusal fibers by the gamma motoneurons, serves to modulate the sensitivity of the intrafusal fibers. That is, the gamma motoneurons cause corresponding contraction of the contractile portions of the intrafusal fibers, which stretch the central noncontractile region of the intrafusal fibers. Thus, the sensitivity of the intrafusal fibers is constantly maintained by continuously readapting to the most current status of muscle length. In this fashion the muscle spindles can detect a change in muscle length (resulting from stretch or contraction) irrespective of muscle length at the onset of muscle activity. It should be noted that even though they contract, the intrafusal fibers, due to their small number and size, do not contribute to any significant extent to the overall contraction of a gross muscle.

Simple stretch reflex

The **simple stretch reflex**, whose mechanism is based on the role of the intrafusal fibers, functions to maintain muscle length caused by external disturbances. As a muscle is stretched, the intrafusal fibers of the muscle spindles are also stretched. This in turn stimulates the sensory afferent annulospiral and flower spray endings to transmit this information to those alpha motoneurons of the CNS (spinal cord, or cranial nerve motor nuclei) that innervate the agonist (stretched) muscle as well as to those motoneurons that innervate the antagonist muscle(s). The degree of stretching is proportional to (or related to) the load placed on the muscle. The larger the load, the more strongly the spindles are depolarized and the more extrafusal muscle fibers are in turn activated. As these alpha motoneurons of the stretched muscle fire, they stimulate the contraction of the required number of extrafusal muscle fibers of the *agonist* muscle. The alpha motoneurons of the *antagonist* muscle(s) are inhibited so the antagonist muscle relaxes. The simple reflex arc involves the firing of only two neurons—an **afferent sensory neuron** and an **efferent motoneuron**—providing dynamic information concerning the changes of the load on the muscle and position of the body region in three-dimensional space.

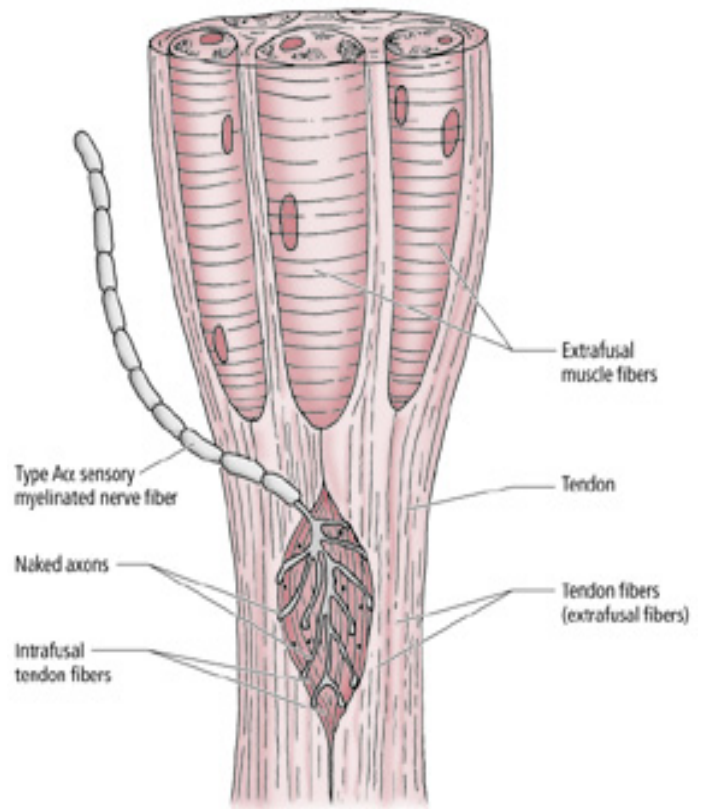


Figure 10.9 ● A Golgi tendon organ (neurotendinous spindle).

Golgi tendon organs

GTOs (neurotendinous spindles) are fusiform-shaped receptors located at sites where muscle fibers insert into tendons

Unlike muscle spindles, which are oriented parallel to the longitudinal axis of the extrafusal muscle fibers, GTOs are *in series*. Furthermore, GTOs do not receive motor innervation as the muscle spindles do. GTOs consist of interlacing **intrafusal** collagen bundles enclosed in a connective tissue capsule (Fig. 10.9). A large-diameter, type A α sensory fiber, whose cell body is housed in a dorsal root sensory ganglion or a cranial nerve sensory ganglion, passes through the capsule and then branches into numerous delicate terminals that are interposed among the intrafusal collagen bundles. The central processes of these A α afferent neurons enter the spinal cord via the dorsal roots of the spinal nerves to terminate and establish synaptic contacts with inhibitory interneurons that, in turn, synapse with alpha motoneurons supplying the contracted agonist muscle.

Combined muscle spindle and Golgi tendon organ functions during changes in muscle length

During slight stretching of a relaxed muscle, the muscle spindles are stimulated while the GTOs remain undisturbed and quiescent; with further stretching both the muscle spindles and GTOs are stimulated

During muscle contraction, as the muscle shortens, tension is produced in the tendons anchoring that muscle to bone, compressing the nerve fiber terminals interposed among the inelastic intrafusal collagen fibers. This compression activates the sensory terminals in the GTOs, which transmit this sensory information to the CNS, providing proprioceptive information concerning muscle activity and preventing the placement of excessive forces on the muscle and tendon. In contrast, the noncontractile portions of the muscle spindles are not stretched, and are consequently undisturbed. The contractile regions of the muscle spindles, however, undergo corresponding contraction that enables them to detect a future change in muscle length (resulting from stretch or contraction).

During slight stretching of a relaxed muscle, the muscle spindles are stimulated whereas the GTOs remain undisturbed and quiescent. During further stretching of the muscle, which produces tension on the tendons, both the muscle spindles and the GTOs are stimulated. Thus GTOs monitor and check the amount of tension exerted on the muscle (regardless of whether it is tension generated by muscle stretch or contraction), whereas muscle spindles check muscle fiber length and rate of change of muscle length (during muscle stretch or contraction).

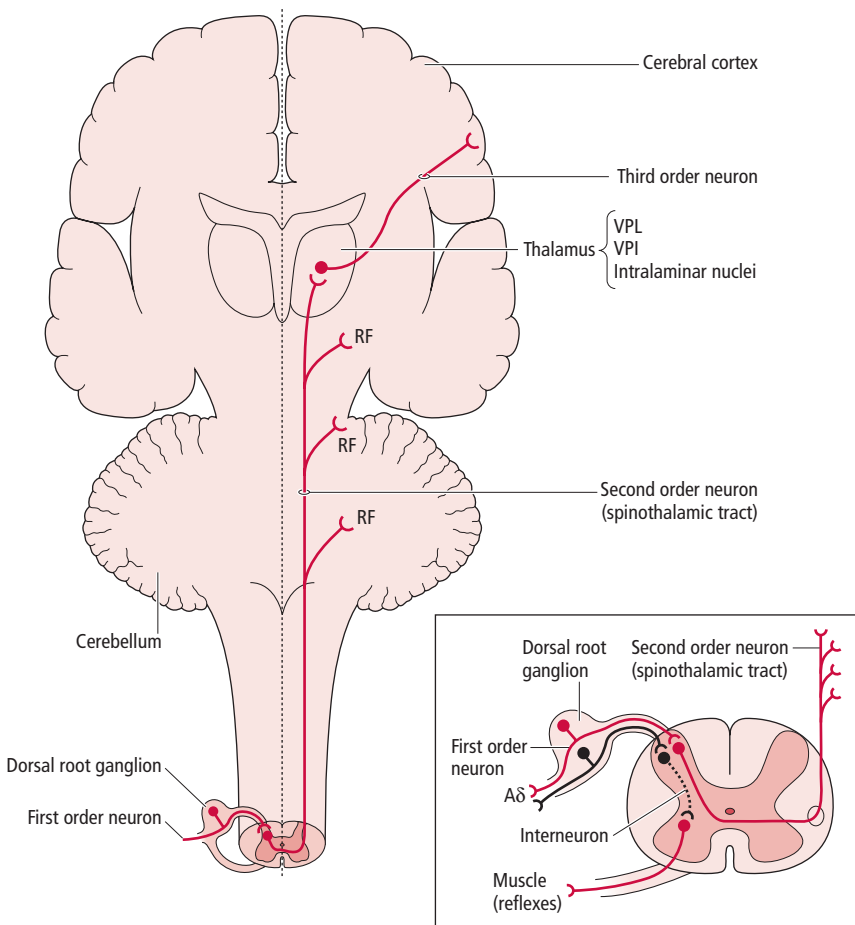


Figure 10.10 ● The direct pathway of the anterolateral system. Note the first order neuron in the dorsal root ganglion, the second order neuron in the dorsal horn of the spinal cord, and the third order neuron in the thalamus. The second order neuron sends collaterals to the reticular formation (RF). VPI, ventral posterior inferior; VPL, ventral posterior lateral.

ANTEROLATERAL SYSTEM

The ALS transmits nociceptive, thermal, and nondiscriminatory touch information to higher brain centers, generally by a sequence of three neurons and interneurons

The anterolateral system (ALS) transmits nociceptive, thermal, and nondiscriminatory (crude) touch information to higher brain centers (see Table 10.2), generally by

a sequence of three neurons and interneurons (Fig. 10.10). The neuron sequence consists of:

- 1 A **first order neuron** (pseudounipolar neuron) whose cell body is located in a dorsal root ganglion. It transmits sensory information from peripheral structures to the dorsal (posterior) horn of the spinal cord.
- 2 A **second order neuron** whose cell body is located within the dorsal horn of the spinal cord, and whose axon usually decussates and ascends:
 - in the **direct pathway of the ALS (spinothalamic tract)** to synapse in the contralateral thalamus, and sending some collaterals to the reticular formation;
 - in the **indirect pathway of the ALS (spinoreticular tract)** to synapse in the reticular formation, and sending some collaterals to the thalamus; or

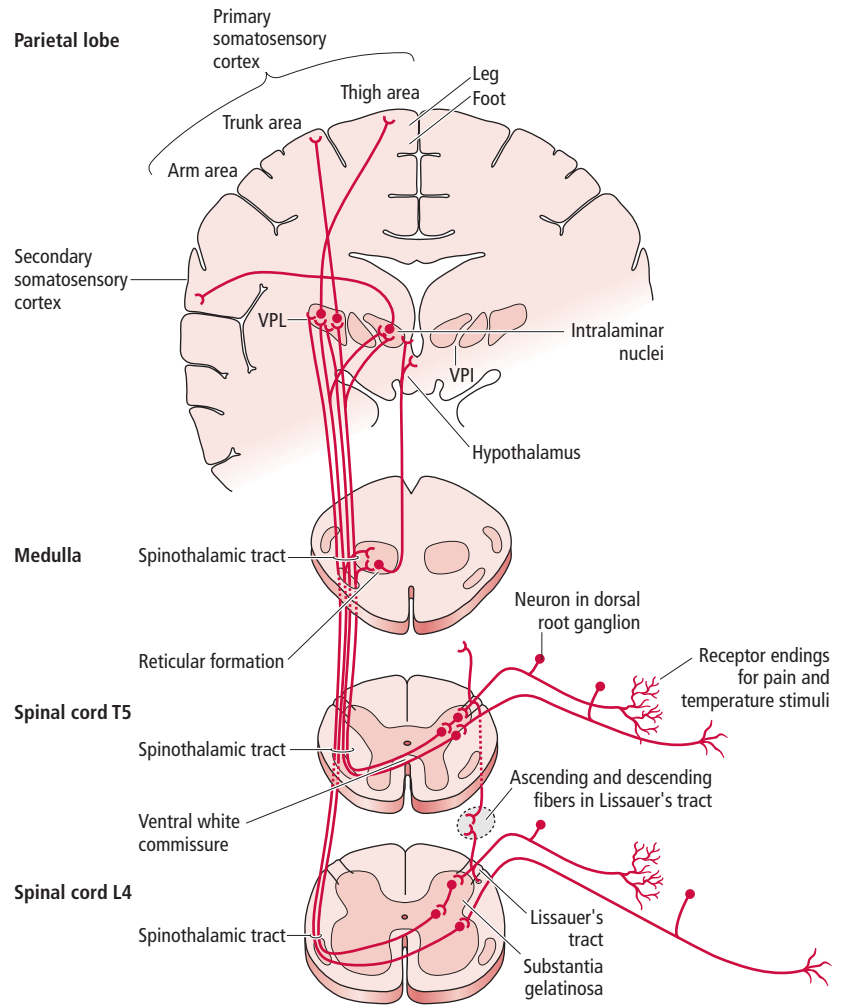


Figure 10.11 ● The ascending sensory pathway that transmits nondiscriminative (crude) touch, pain, and temperature sensations from the body. (Modified from Gilman, S, Winans Newman, S (1992) *Essentials of Clinical Neuroanatomy and Neurophysiology*. FA Davis, Philadelphia; fig. 19.)

- as **spinomesencephalic**, **spinothalamic**, or **spinohypothalamic fibers** to synapse in several brainstem nuclei.

3 A **third order neuron** whose cell body is located in the thalamus, and whose axon ascends ipsilaterally to terminate in the somatosensory cortex.

In some cases, the first order neuron may synapse with an **interneuron** that resides entirely within the dorsal horn, and whose axon synapses with the second order neuron.

Pain pathways from the body

First order neurons (sensory receptors)

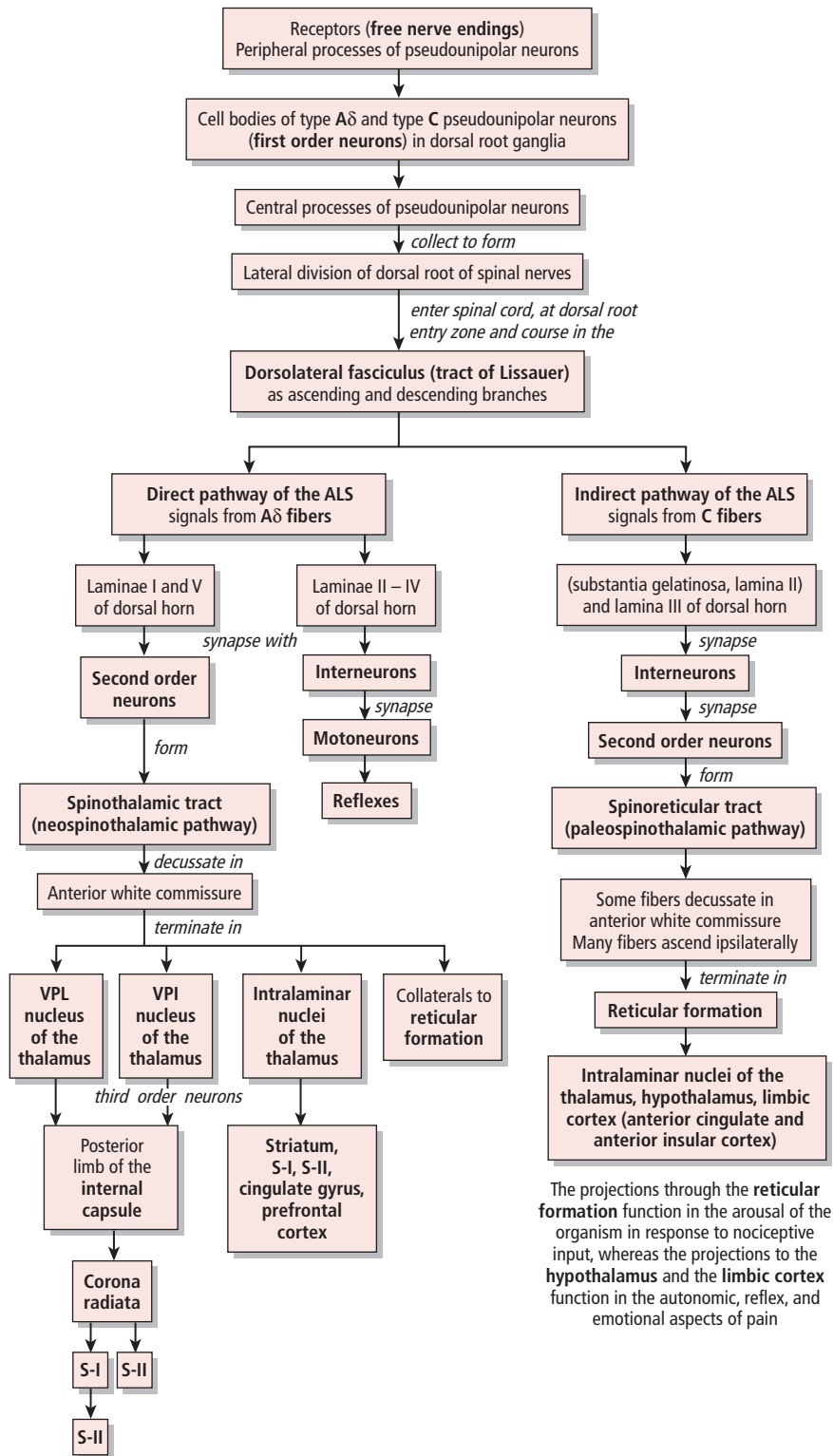
Receptors that transmit nociceptive information consist of high-threshold free nerve endings ramifying near the external surface and internal environment of the organism

Receptors that transmit nociceptive information consist of high-threshold free nerve endings ramifying near the external surface and internal environment of the organism. These are dendritic arborizations of small, pseudounipolar,

first order neurons (Fig. 10.11) whose somata are housed in a dorsal root ganglion. The peripheral processes of these pseudounipolar neurons consist of two main types of fiber (Fig. 10.12):

- 1 Thinly myelinated **Aδ (fast-conducting) fibers**, which relay sharp, short-term, well-localized pain (such as that resulting from a pinprick). These fibers transmit sensations that do not elicit an affective component associated with the experience.
- 2 Unmyelinated **C (slow-conducting) fibers**, which relay dull, persistent, poorly localized pain (such as that resulting from excessive stretching of a tendon). These fibers transmit sensations that elicit an affective response.

The central processes of these pseudounipolar neurons enter the spinal cord at the dorsal root entry zone, via the lateral division of the dorsal roots of the spinal nerves, and upon entry collectively form the **dorsolateral fasciculus (tract of Lissauer)**, which is present at all spinal cord levels. These central processes bifurcate into short ascending and descending branches. These branches either ascend or descend one to three spinal cord levels within this tract, to terminate in their



The projections through the **reticular formation** function in the arousal of the organism in response to nociceptive input, whereas the projections to the **hypothalamus** and the **limbic cortex** function in the autonomic, reflex, and emotional aspects of pain

The **postcentral gyrus (S-I)** is the site where processing of pain localization, intensity, quality, and sensory integration takes place at the conscious level; **S-II** functions in the memory of sensory input

Figure 10.12 ● The spinothalamic (direct) and spinoreticular (indirect) pathways of the anterolateral system (ALS) transmitting nondiscriminative (crude) touch, pain, and temperature sensation from the body. VPI, ventral posterior inferior; VPL, ventral posterior lateral.

target laminae of the dorsal horn, where they synapse with second order neurons (or with interneurons). Therefore, although stimulation of the peripheral endings of fibers carried by one spinal nerve may enter the spinal cord at a specific spinal level, collaterals of the ascending and descending branches spread the signal to neighboring spinal levels above and below the level of entry. These collaterals play an important function in intersegmental reflexes.

Second order neurons

The cell bodies of the second order neurons transmitting nociception reside in the dorsal horn of the spinal cord

The cell bodies of the second order neurons transmitting nociception reside in the dorsal horn of the spinal cord (Fig. 10.12). Recent findings indicate that the axons of these second order neurons course in either the **direct (spinothalamic)** or **indirect (spinoreticular)** pathways of the ALS, or as three sets of fibers (the remaining components of the ALS): the **spinomesencephalic**, **spinotectal**, or **spinothalamal fibers**. Approximately 15% of nociceptive fibers project directly to the thalamus whereas 85% project to the thalamus via a relay in the reticular formation.

Direct pathway of the anterolateral system

The spinothalamic tract transmits not only nociceptive input, but also thermal and nondiscriminative touch input to the contralateral ventral posterior lateral nucleus of the thalamus

Type **A δ** fibers of first order neurons synapse primarily with **second order neurons** in lamina I (posteromarginal nucleus, or zone) and lamina V (reticular nucleus) of the spinal cord gray matter. However, many first order neurons synapse with spinal cord **interneurons** that are associated with reflex motor activity. The axons of the second order neurons flow across the midline to the contralateral side of the spinal cord in the anterior white commissure, forming the **spinothalamic tract** (Fig. 10.13).

The spinothalamic tract transmits not only nociceptive input, but also thermal and nondiscriminative (crude) touch input to the contralateral ventral posterior lateral nucleus of the thalamus. It also sends some projections to the **ventral posterior inferior**, and the **intralaminar nuclei of the thalamus**. Although the spinothalamic tract ends at the thalamus, as it ascends through the brainstem it also sends collaterals to the reticular formation. Since the spinothalamic tract (direct pathway of the ALS: spinal cord \rightarrow thalamus) is phylogenetically a newer pathway, it is referred to as the **neospinothalamic pathway**.

Only about 15% of the nociceptive fibers from the spinal cord, ascending in the ALS and carrying nociceptive information, terminate directly in the thalamus via the spinothalamic tract. Although referred to as the "spinothalamic tract," it actually consists of two anatomically distinct tracts: the **lateral**

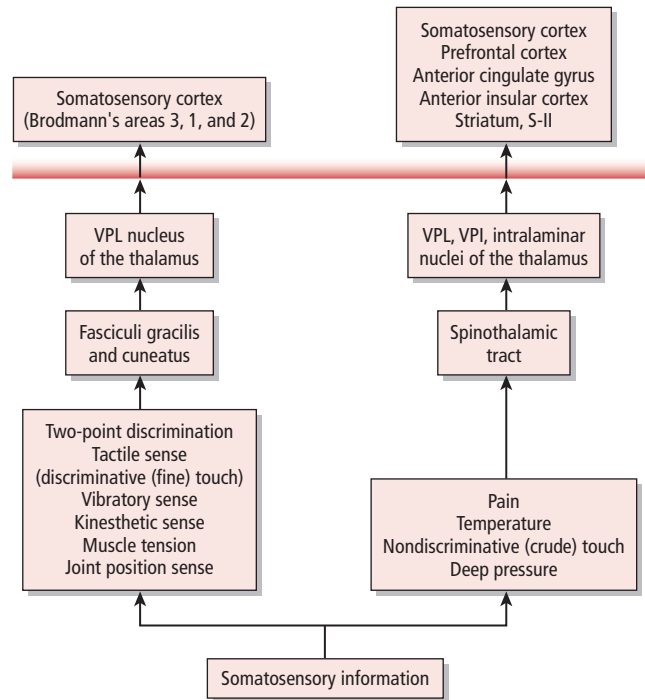


Figure 10.13 ● Somatosensory information to consciousness. VPI, ventral posterior inferior; VPL ventral posterior lateral.

spinothalamic tract (located in the lateral funiculus) and the very small **anterior spinothalamic tract** (located in the anterior funiculus). Earlier studies indicated that the lateral spinothalamic tract transmitted only nociceptive and thermal input, whereas the anterior spinothalamic tract transmitted only nondiscriminative (crude) touch. Recent studies however, support the finding that both the anterior and lateral spinothalamic tracts (as well as the other component fibers of the ALS: spinoreticular, spinomesencephalic, spinotectal, and spinothalamal), transmit **nociceptive**, **thermal**, and **nondiscriminative (crude) tactile signals** to higher brain centers.

Indirect pathway of the anterolateral system

Type C fibers of first order neurons terminate on interneurons in laminae II (substantia gelatinosa) and III of the dorsal horn. Axons of these **interneurons** synapse with **second order neurons** in laminae V–VIII. Many of the axons of these second order neurons ascend ipsilaterally, however a small number of axons sweep to the opposite side of the spinal cord in the anterior white commissure. These axons form the more prominent **ipsilateral** and smaller **contralateral spinoreticular tracts**. The spinoreticular tracts transmit **nociceptive**, **thermal**, and **nondiscriminative (crude) touch** signals from the spinal cord to the thalamus indirectly, by forming multiple synapses in the reticular formation prior to their thalamic projections. Since the spinoreticular tract (indirect pathway of the ALS: spinal cord \rightarrow reticular formation \rightarrow thalamus) is phylogenetically an older pathway, it is referred to as the **paleospinothalamic pathway** (Fig. 10.14).

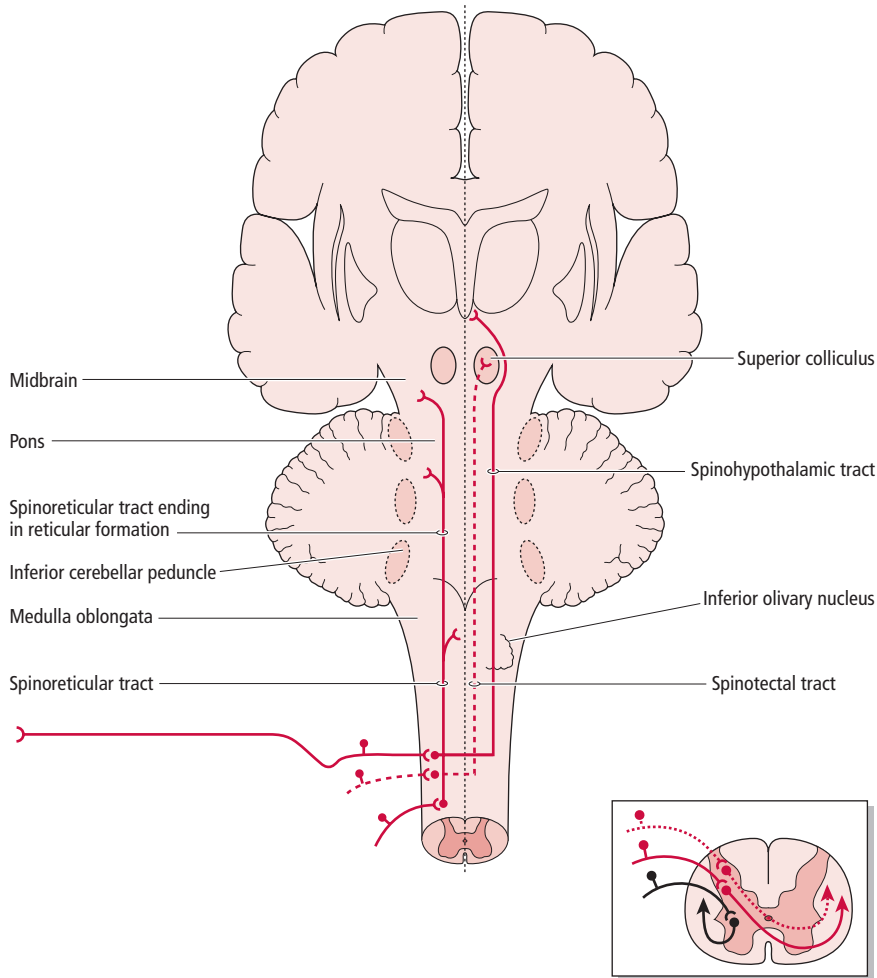


Figure 10.14 ● Spinotectal, spinoreticular, and spinohypothalamic tracts of the indirect pathway of the anterolateral system. Note that the spinomesencephalic tract is not shown.

The spinoreticular tract is a bilateral (primarily uncrossed) tract that conveys sensory information to the brainstem reticular formation, the region responsible for producing arousal and wakefulness, thus alerting the organism following an injury. Impulses from the reticular formation are then relayed bilaterally to the **intralaminar nuclei of the thalamus**, via reticulothalamic fibers. Since these nuclei lack somatotopic organization, there is only an indistinct localization of sensory signals carried by this pathway. The reticular formation and its continuation into the diencephalon, the intralaminar nuclei of the thalamus, are components of the **reticular-activating system (RAS)**. The RAS functions in activating the organism's entire nervous system, so as to elicit responses that will enable it to evade painful stimuli. In addition, there are some second order neurons from the dorsal horn that bypass the reticular formation and relay sensory input from C fibers directly to the intralaminar nuclei of the thalamus.

Other component fibers of the anterolateral system

In addition to the spinothalamic and spinoreticular tracts, the ALS also contains spinomesencephalic, spinotectal, and spinohypothalamic fibers

The **spinomesencephalic fibers** terminate in the periaqueductal gray matter and the midbrain raphe nuclei, both of which are believed to give rise to fibers that modulate nociceptive transmission and are thus collectively referred to as the “descending pain-inhibiting system” (see discussion later). Furthermore, some spinomesencephalic fibers terminate in the parabrachial nucleus, which sends fibers to the amygdala—a component of the limbic system associated with the processing of emotions. Via their connections to the limbic system, the spinomesencephalic fibers play a role in the emotional component of pain.

The **spinotectal fibers** terminate mainly in the deep layers of the superior colliculus. The superior colliculi have the reflex function of turning the upper body, head, and eyes in the direction of a painful stimulus (Fig. 10.14).

The **spinohypothalamic fibers** ascend to the hypothalamus where they synapse with neurons that give rise to the hypothalamospinal tract. This pathway is associated with the autonomic and reflex responses (i.e., endocrine and cardiovascular) to nociception (Fig. 10.14).

Approximately 85% of the nociceptive fibers from the spinal cord ascending in the ALS, terminate in the brainstem reticular formation. From there, the information eventually reaches the thalamus via multiple additional synapses that

occur in the brainstem. The reticular formation sends fibers transmitting nociceptive input not only to the thalamus but also to the hypothalamus, which is associated with the autonomic and reflex responses to nociception, and the limbic system, which mediates the emotional component of nociception.

Third order neurons

Cell bodies of third order neurons of the nociception-relaying pathway are housed in: the ventral posterior lateral, the ventral posterior inferior, and the intralaminar thalamic nuclei

The **ventral posterior lateral nucleus** gives rise to fibers that course in the **posterior limb of the internal capsule** and in the **corona radiata** to terminate in the **postcentral gyrus** (primary somatosensory cortex, S-I) of the parietal lobe of the cerebral cortex. Additionally, the ventral posterior lateral nucleus also sends some direct projections to the secondary somatosensory cortex, S-II (Fig. 10.15).

The **ventral posterior inferior nucleus** projects mostly to the **secondary somatosensory cortex (S-II)**, although some of its fibers terminate in the **primary somatosensory cortex (S-I)**.

The **intralaminar nuclei** send fibers to the **striatum** (the **caudate nucleus** and the **putamen**), the **S-I** and **S-II**, as well as to the **cingulate gyrus** and the **prefrontal cortex**.

It should be noted that most of the nociception-relaying fibers arriving at the **intralaminar nuclei** transmit nociceptive information relayed there from the reticular formation. Multiple synapses have been formed in the reticular formation prior to synapsing in the intralaminar nuclei, and thus, strictly speaking, the intralaminar relay neurons for this pathway are not the third order neurons in the sequence, but they function as if they were third order neurons.

Projections to the somatosensory (somesthetic) cortex

The **primary somatosensory cortex (S-I)** consists of the postcentral gyrus of the parietal lobe, which corresponds to

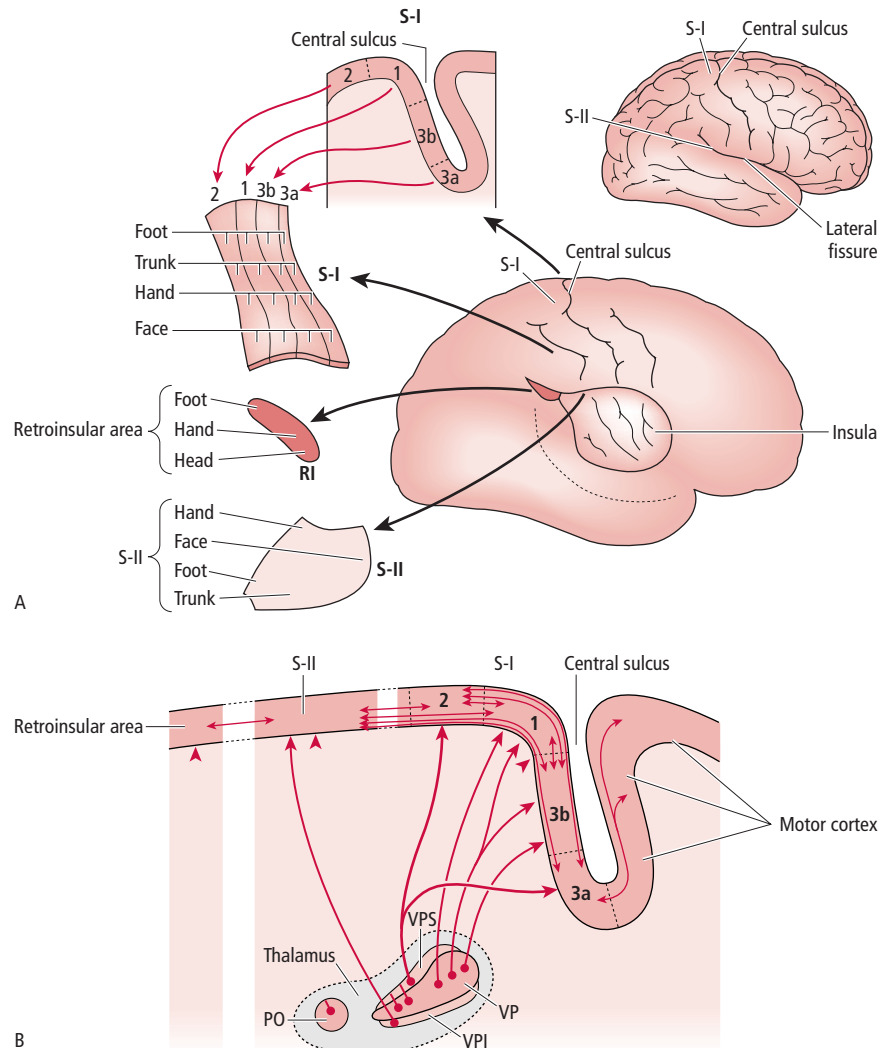


Figure 10.15 ● Primary and secondary somatosensory cortex and retroinsular cortex: three major cortical areas receiving somatosensory information from the thalamus. (A) Counter clockwise from top right: lateral view of the brain; a cross-section of the central sulcus (of Rolando); and the primary somatosensory cortex (postcentral gyrus, S-I) forming the posterior border of the sulcus. Note the components of the primary somatosensory cortex areas 3a, 3b, 1, and 2, and the cortical representation of the foot, trunk, hand, and face. The lateral view of the brain shows the exposed insular cortex, secondary somatosensory cortex (S-II), and retroinsular (RI) cortex. (B) Thalamocortical projections to the primary somatosensory cortex (S-I), secondary somatosensory cortex (S-II), and retroinsular cortex (RI). PO, posterior complex; VP, ventral posterior; VPI, ventral posterior inferior; VPS, ventral posterior superior. (Modified from Burt, AM (1993) *Textbook of Neuroanatomy*. WB Saunders, Philadelphia; figs 10.20, 10.22.)

Brodmann's areas 3a, 3b, 1, 2 (Fig. 10.15A). The **secondary somatosensory cortex** (S-II) consists of Brodmann's area 43, located on the superior bank of the lateral fissure, at the inferior extent of the primary motor and sensory areas.

Axons of the thalamic third order neurons terminate in somatotopically corresponding regions of the primary somatosensory cortex. Regions of the head are represented in the inferior half of the postcentral gyrus near the lateral fissure, whereas those of the upper limb and the trunk are represented in its superior half. The lower limb is represented in the medial surface of the postcentral gyrus, and the perineum in the paracentral lobule. The body areas with the largest cortical area representation are the head and upper limb, reflecting the great discriminative capability that structures in these regions possess (Fig. 10.16).

In summary, nociceptive signals relayed from the spinal cord directly to the ventral posterior lateral, the ventral posterior inferior, and the intralaminar nuclei of the thalamus via the spinothalamic tract (neospinothalamic, direct pathway of the ALS) are transmitted to the somatosensory cortex (both to S-I and S-II). The postcentral gyrus is the site where processing of pain localization, intensity, quality, and sensory integration takes place at the conscious level. The primary somatosensory cortex sends projections to the secondary somatosensory cortex, which is believed to have an important function in the memory of sensory input.

In contrast, nociceptive signals relayed from the spinal cord to the reticular formation via the spinoreticular tracts (paleospinothalamic, indirect pathway of the ALS) are then transmitted to:

- the **intralaminar nuclei of the thalamus** (the cranial extension of the reticular formation into the thalamus), which in turn project to the primary somesthetic cortex;
- the **hypothalamus**; and
- the **limbic system**.

The projections through the reticular formation function in the arousal of the organism in response to nociceptive input, whereas the projections to the hypothalamus and limbic system have an important function in the autonomic, reflex, and emotional (suffering) responses to a painful experience.

Projections to the cingulate and insular cortices

Cerebral imaging studies such as electroencephalography (EEG), functional magnetic resonance imaging (fMRI), magnetoencephalography (MEG), and positron emission tomography (PET) have demonstrated that nociceptive signals are not only processed at the primary and secondary

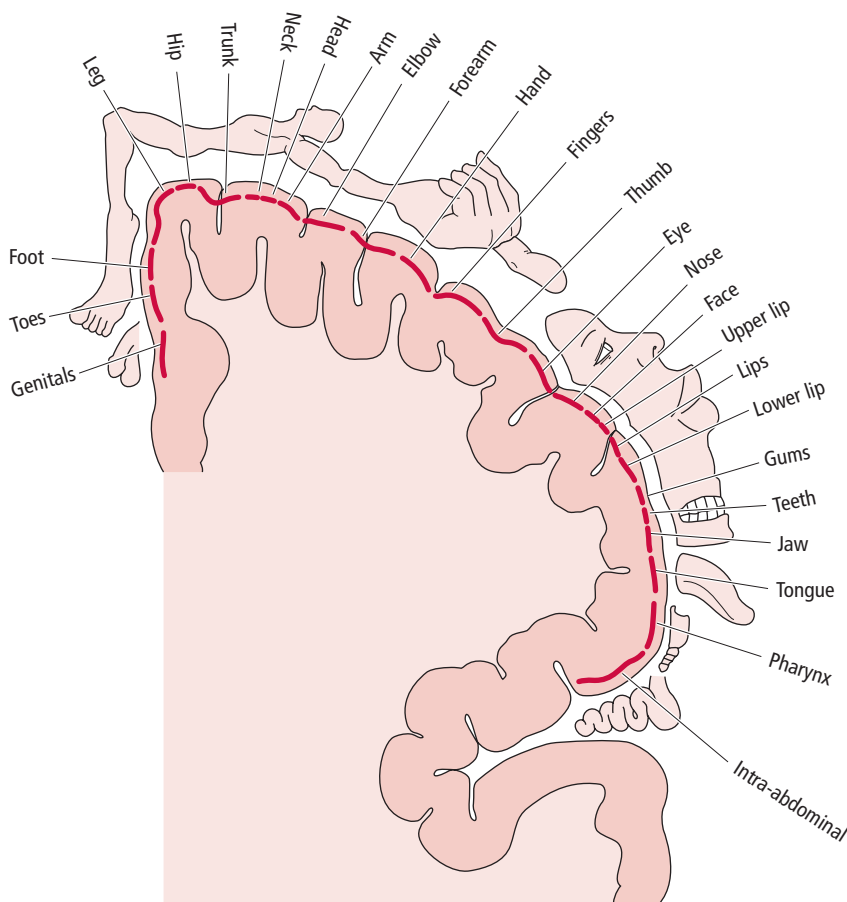


Figure 10.16 ● Coronal section through the primary somatosensory cortex (postcentral gyrus), showing the sensory homunculus. Note that the amount of cerebral cortex representing each body part is proportional to the extent of its motor innervation.

somatosensory cortices, but also in the **anterior cingulate cortex**, **anterior insular cortex**, and even the **supplemental motor area** of the motor cortex. The anterior cingulate and anterior insular cortices are connected with the limbic cortex, which plays a role in the emotional aspect of pain.

Visceral pain

A striking characteristic of the brain is that although it receives and processes nociceptive information, the brain itself has no sensation of pain

A striking characteristic of the brain is that although it receives and processes nociceptive information, the brain itself has no sensation

of pain. During brain surgery, the patient is often awake and has no pain sensation from the brain tissue itself. The structures that have to be anesthetized during brain surgery are the dura mater, the bones of the skull, and the extracranial soft tissues. Moreover, although the internal (visceral) organs themselves have no pain receptors, pain receptors are present embedded in the walls of the arteries serving these organs.

Visceral pain is characterized as diffuse and poorly localized, and is often “referred to” and felt in another somatic structure distant or near the source of visceral pain. Nociceptive signals from the viscera generally follow the same pathway as signals arising from somatic structures. General visceral afferent nociceptive information from visceral structures of the trunk is carried mostly by type **C**, **Aδ**, or **Aβ** fibers (Fig. 10.17). The peripheral terminals of these fibers are associated with Pacinian corpuscles that respond to excessive stretching of the intestinal wall, a lesion in the wall of the gastrointestinal tract, or to smooth muscle spasm. The cell bodies of these sensory (pseudounipolar), **first order neurons** are housed in the dorsal root ganglia, and their central processes carry the information, via the **dorsolateral fasciculus (tract of Lissauer)**, to the dorsal horn and lateral gray matter of the spinal cord. Here, these central processes synapse with second order neurons as well as with neurons associated with reflex activities.

The axons of the **second order neurons** join the **anterolateral system** to relay nociceptive signals from visceral structures to the **reticular formation** and the **thalamus**. Fibers from the reticular formation project to the **intralaminar nuclei of the thalamus**, which in turn project to the **cerebral cortex** and the **hypothalamus**. Recall that the intralaminar nuclei of the thalamus lack somatotopic organization, resulting in only an indistinct localization of sensory signals carried by this pathway.

Visceral pain signals relayed to the primary somatosensory cortex may be associated with referred pain to a somatic structure. In addition to projections to the somatosensory cortex, recent studies indicate that nociceptive signals are also relayed to the **anterior cingulate** and **anterior insular cortices**, two cortical areas implicated in the processing of visceral pain.

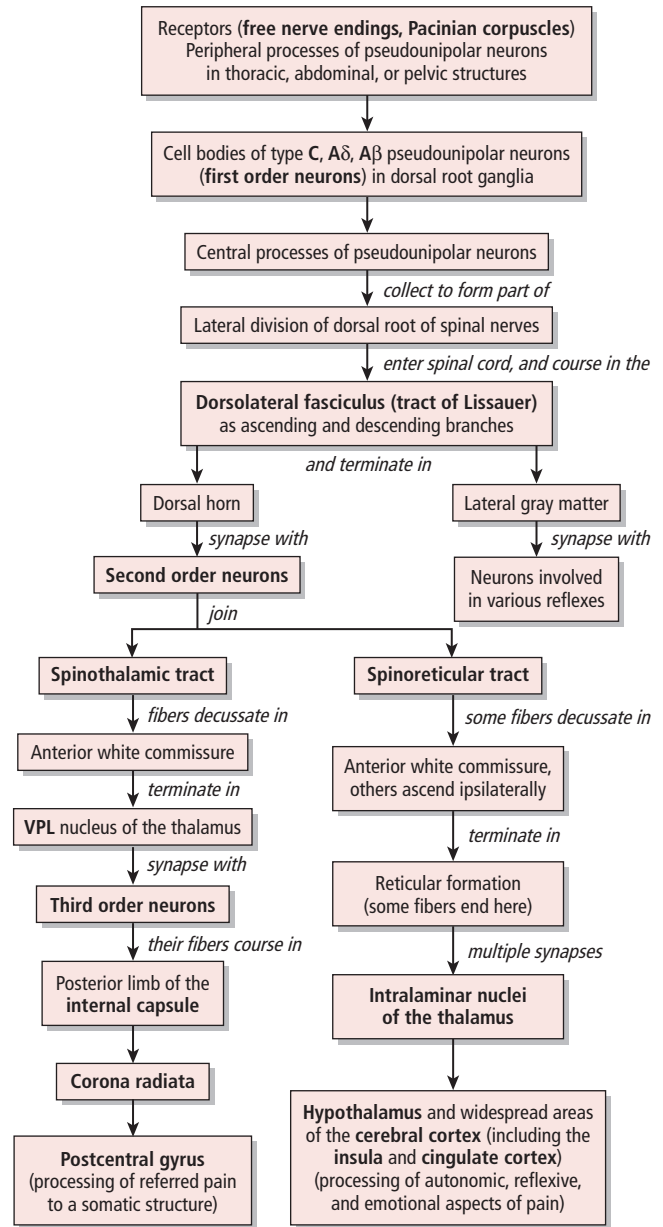


Figure 10.17 ● The ascending sensory pathway relaying pain sensation from the viscera. VPL ventral posterior lateral.

Temperature pathways from the body

Temperature sensory input is transmitted to the CNS via unmyelinated C fibers that are activated by warm stimuli, or by lightly myelinated Aδ fibers that are activated by cold stimuli

Temperature sensory input is transmitted to the CNS via unmyelinated C fibers that are activated by warm stimuli, or by lightly myelinated Aδ fibers that are activated by cold stimuli (see Fig.

10.12; Table 10.2).

All fibers enter the spinal cord at the dorsal root entry zone in the lateral division of the dorsal root of the spinal nerves. These fibers accompany nociceptive fibers and, upon

Table 10.3 ● Ascending sensory pathways to consciousness.

Sensation	Sensory receptor	Location of cell body of first order neuron	Location of cell body of second order neuron (origin of pathway)	Pathway	Decussation
Pain and thermal sense from the body	A δ and C fiber endings	Dorsal root ganglion	Dorsal horn	Spinothalamic tract of ALS	Anterior white commissure
Nondiscriminative (crude) touch and superficial pressure from the body	Free nerve endings, Merkel's discs, peritrichial nerve endings	Dorsal root ganglion	Dorsal horn	Spinothalamic tract of ALS	Anterior white commissure
Two-point discriminative (fine) touch, vibratory sense, proprioceptive sense from muscles and joints of body	Meissner's corpuscles, Pacinian corpuscles, muscle stretch receptors, Golgi tendon organs	Dorsal root ganglion	Nucleus gracilis, nucleus cuneatus	First order fibers: fasciculi gracilis and cuneatus Second order fibers: medial lemniscus	Medial lemniscal decussation

ALS, anterolateral system; VPI, ventral posterior inferior; VPL, ventral posterior lateral.

entering the spinal cord, join the **dorsolateral fasciculus (tract of Lissauer)**. In the dorsolateral fasciculus, they bifurcate into short *ascending* and *descending* fibers. These fibers ascend or descend respectively, one to three spinal cord levels to synapse in laminae I, II, and III of the dorsal horn gray matter. Temperature input is relayed to **interneurons** which, in turn, transmit the information to **second order neurons** in lamina V.

The axons of the second order neurons, accompanied by nociceptive fibers, decussate in the anterior white commissure to join the contralateral **anterolateral system**. Some of these fibers ascend to terminate in the brainstem **reticular formation**; however, most terminate primarily in the **ventral posterior lateral nucleus of the thalamus**. **Third order neuron** fibers from the thalamus relay thermal sensory information to the **somesthetic cortex**.

TACTILE SENSATION AND PROPRIOCEPTION

Tactile sensation is divisible into nondiscriminative (crude) touch and discriminative (fine) touch

Tactile sensation is divisible into nondiscriminative (crude) touch and discriminative (fine) touch. Crude touch, transmitted via the ALS (discussed above), is sensed following gentle stroking of the skin with a fine cotton strand, but this sensation does not include detailed information about the stimulus. Tactile examination of an object is dependent on discriminative (fine) touch sense, which enables one to detect fine detail regarding the location, size, shape, and texture of an object even when the eyes are closed.

Conscious proprioception may be categorized into static and dynamic proprioception. **Static proprioception (static**

position sense) is the awareness of the position of a body part such as a limb, whereas **dynamic proprioception (kinesthetic sense)** is the awareness of movement of a body part, and balance.

Discriminative (fine) touch, pressure, vibratory sense, as well as **proprioceptive** sensory information are transmitted to higher brain centers, reaching consciousness, by three neurons arranged in sequence (Fig. 10.18; Table 10.3).

- 1 A **first order neuron** (pseudounipolar neuron) whose cell body is located in a dorsal root ganglion. The neuron transmits sensory information from the periphery to the spinal cord (for reflex activity) and to the **dorsal column nuclei** (the **nucleus gracilis** and the **nucleus cuneatus**).
- 2 A **second order neuron** whose cell body is located in the **dorsal column nuclei** in the medulla, and whose axon decussates and ascends to terminate in the contralateral **thalamus**.
- 3 A **third order neuron** whose cell body resides in the **thalamus**, and whose axon ascends ipsilaterally to terminate in the **somatosensory cortex**. The specifics of these pathways are discussed below.

Discriminative (fine) touch and pressure sense from the body

First order neurons (sensory receptors)

The receptors that transmit discriminative (fine) touch, pressure, and conscious proprioception information consist of:

Table 10.3 ● Continued.

Location of pathway in spinal cord	Pathway (second order neuron) termination	Location of cell body of third order neuron	Termination of third order neuron	Conscious/subconscious	Function(s)
Lateral funiculus	VPL, VPI, and intralaminar nuclei of the thalamus	VPL nucleus of the thalamus Intralaminar nuclei	Postcentral gyrus Cingulate gyrus Prefrontal cortex	Conscious	Relays pain and thermal sensation from the body
Anterior funiculus	VPL nucleus of the thalamus	VPL nucleus of the thalamus	Postcentral gyrus	Conscious	Relays nondiscriminative (crude) touch sensation from the body
Posterior funiculus	VPL nucleus of the thalamus	VPL nucleus of the thalamus	Postcentral gyrus	Conscious	Relays two-point discriminative (fine) touch tactile sensation, vibratory sense, proprioceptive sense from muscles and joints of the body
Medulla					

- **free nerve endings** responding to touch, pressure, and proprioception in the skin, muscles, and joint capsules;
- **tactile (Merkel’s) discs** responding to touch and pressure in the skin;
- **peritrichial endings** stimulated by touch of the hair follicles;
- **Meissner’s corpuscles** activated by touch of the skin; and
- **Pacinian corpuscles** stimulated by touch, pressure, vibration, and proprioception in the deep layers of the skin, and in visceral structures.

These **first order pseudounipolar neurons**, whose cell bodies are located in the dorsal root ganglia, send peripheral processes to somatic or visceral structures. These peripheral processes are medium-size type **Aβ** and large-size type **Aα fibers**. Upon being stimulated, the peripheral processes transmit the sensory information to the spinal cord by way of the central processes of the pseudounipolar neurons, which enter the spinal cord at the dorsal root entry zone via the medial division of the dorsal roots of the spinal nerves. Upon entry into the posterior funiculus of the spinal cord, the afferent fibers bifurcate into long ascending and short descending fibers.

Bifurcating fibers

The long ascending and short descending fibers give rise to collateral branches that may synapse with several distinct cell groups of the dorsal horn interneurons and with ventral horn motoneurons. These fibers collectively form the **dorsal column pathways**, either the **fasciculus gracilis** or the **fasci-**

culus cuneatus, depending on the level of the spinal cord in which they enter.

Below level T6

The central processes that enter the spinal cord below level T6 include the lower thoracic, lumbar, and sacral levels that bring information from the lower limb and lower half of the trunk

The central processes that enter the spinal cord below level T6 include the lower thoracic, lumbar, and sacral levels. They bring information from the lower limb and lower half of the trunk. The central processes enter the ipsilateral **fasciculus gracilis** (L. gracilis, “slender”) and ascend to the medulla to terminate in the ipsilateral **nucleus gracilis**. It should be recalled that the fasciculus gracilis is present in the entire length of the spinal cord.

Level T6 and above

The central processes that enter the spinal cord at level T6 and above bring information from the upper thoracic and cervical levels, that is from the upper half of the trunk and upper limb

The central processes that enter the spinal cord at level T6 and above bring information from the upper thoracic and cervical levels, that is from the upper half of the trunk and upper limb. These central processes enter the ipsilateral **fasciculus cuneatus** (L. cuneus, “wedge”) and ascend to the medulla to synapse with second order neurons in the ipsilateral **nucleus cuneatus**. It should be noted that the fasciculus cuneatus is present only at the upper six thoracic and at all cervical spinal cord levels.

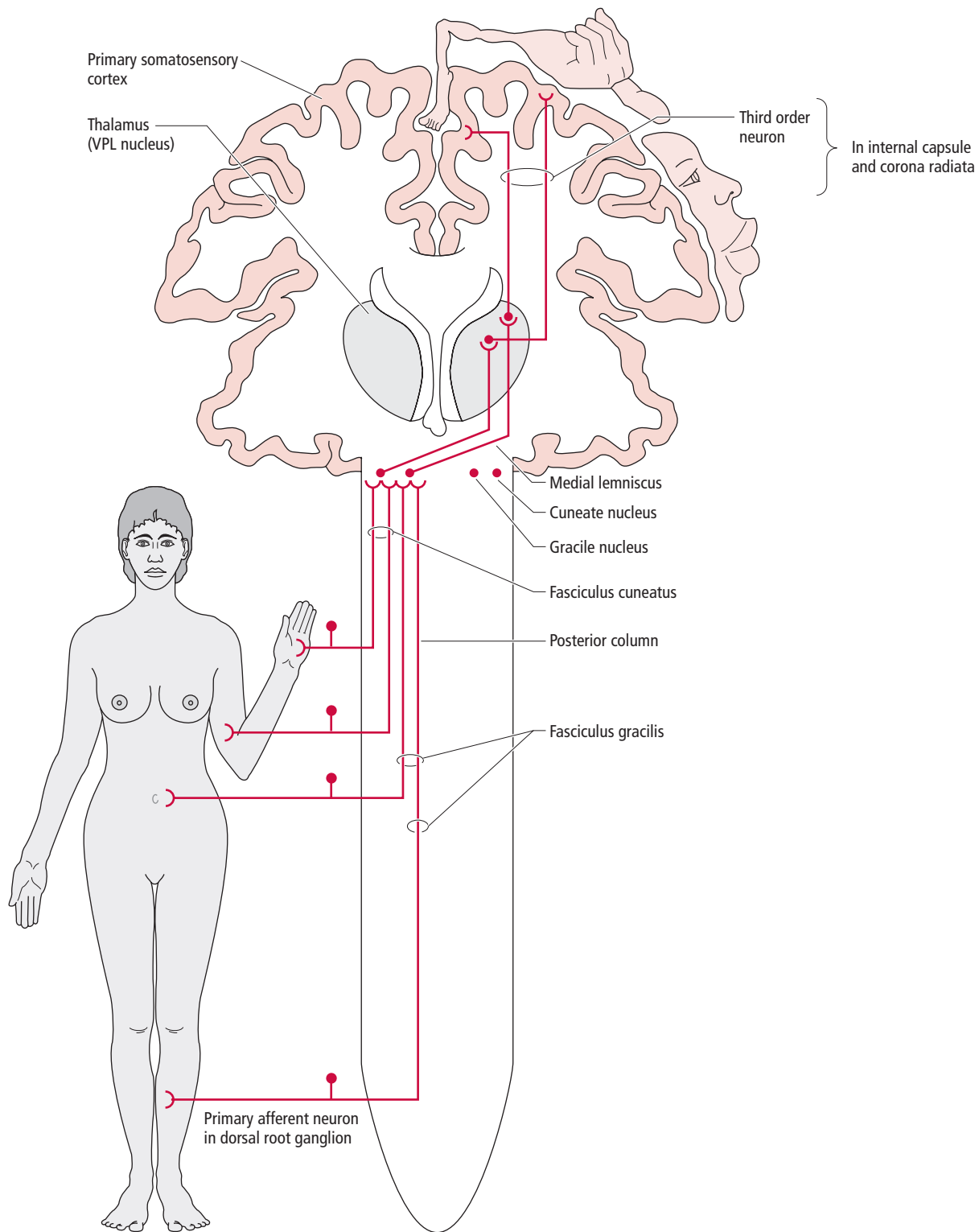
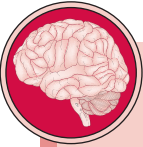

Figure 10.18 ● The dorsal column–medial lemniscal pathway relaying discriminative (fine) touch and vibratory sense from the body to the somatosensory cortex. VPL, ventral posterior lateral.



Note that the clinical case at the beginning of the chapter refers to a patient who has a sensory disturbance of the distal upper and lower limbs. Symptoms include numbness and tingling of the hands and legs, incoordination in movements of the hands, imbalance, and difficulty walking. Sensation, particularly to vibration and joint position, is severely impaired in the distal limbs.

- 1 Which ascending sensory pathway(s) is/are affected in this patient?
- 2 Where are the nerve cell bodies of the affected pathways located?
- 3 In which part of the spinal cord are the affected ascending pathways located?
- 4 How extensive is the damage if symptoms are present in both the upper and lower limbs?

As the descending fibers of all of the first order neurons descend to various spinal cord levels within the fasciculus gracilis or the fasciculus cuneatus, they give rise to collateral branches along the way. These collateral branches form synapses with interneurons and alpha motoneurons, thus participating in intersegmental reflexes.

Second order neurons

The first order fibers terminating in the nucleus gracilis and nucleus cuneatus synapse with second order neurons whose cell bodies are housed in these nuclei

The first order fibers terminating in the nucleus gracilis and nucleus cuneatus synapse with second order neurons whose cell bodies are housed in these nuclei. The fibers of the second order neurons form the **internal arcuate fibers** as they curve ventromedially through the reticular formation to the opposite side. These fibers ascend as the **medial lemniscus** (L. lemniscus, “ribbon”) in the caudal part of the medulla, cranial to the prominent pyramidal (motor) decussation, to synapse with third order neurons in the **ventral posterior lateral nucleus of the thalamus**.

Third order neurons

The ventral posterior lateral nucleus of the thalamus houses the cell bodies of the third order neurons of the DCML pathway

The ventral posterior lateral nucleus of the thalamus houses the cell bodies of the third order neurons of the DCML pathway. The fibers arising from the thalamus ascend in the **posterior limb of the internal capsule** and the **corona radiata** to terminate in the primary somatosensory cortex of the **postcentral gyrus** (which occupies Brodmann’s areas 3a, 3b, 1, and 2, of the parietal cortex).

Projections to the somatosensory cortex

Brodmann’s area 3b receives most of the projections arising from the ventral posterior lateral nucleus of the thalamus, and is where initial cortical processing of tactile discrimination input occurs

Brodmann’s area 3b receives most of the projections arising from the ventral posterior lateral nucleus of the thalamus, and is the site where the initial cortical processing of tactile discrimination input takes place. Brodmann’s area 3b in turn projects to Brodmann’s areas 1 and 2. Area 1 is responsible for determining the *texture* and area 2 the *size* and *shape* of objects. In contrast, area 3a is stimulated by signals arising from muscle spindles and is believed to participate in motor functions.

The primary somatosensory cortex projects to the secondary somatosensory cortex, located on the superior border of the lateral fissure. Some third order neuron fibers from the thalamus terminate directly in the secondary somatosensory cortex.

SENSORY PATHWAYS TO THE CEREBELLUM

Most of the proprioceptive information does not reach conscious levels, and instead is transmitted directly to the cerebellum

Only a small portion of the proprioceptive information enters consciousness. Most of the proprioceptive information does not reach conscious levels, and instead is transmitted directly to the cerebellum via the ascending somatosensory cerebellar pathways without projecting to the thalamus or the cerebral cortex. These pathways, which process subconscious proprioception from muscles, tendons, and joints, are two-neuron pathways, consisting of first order and second order neurons. The pathways include (Fig. 10.19; Tables 10.1, 10.4): the dorsal (posterior) spinocerebellar tract, the cuneocerebellar tract, the ventral (anterior) spinocerebellar tract, and the rostral spinocerebellar tract.

Dorsal (posterior) spinocerebellar tract

The primary function of the dorsal spinocerebellar tract is to relay proprioceptive input from the neuromuscular spindles and GTOs of the ipsilateral trunk and lower limb, to the cerebellum

The primary function of the dorsal (posterior) spinocerebellar tract (Fig. 10.19A; Table 10.5) is to relay proprioceptive input from the neuromuscular spindles and GTOs of the ipsilateral trunk and lower limb, to the cerebellum. It should be recalled, however, that it also relays some touch and pressure sensation from the skin of the ipsilateral trunk and lower limb.

First order neurons (pseudounipolar neurons) whose cell bodies are housed in the dorsal root ganglia send their peripheral processes to the skin, muscles, tendons, and joints. Here they perceive proprioceptive information, which is then transmitted to the spinal cord by their central processes. These central processes join the medial division of the dorsal roots of the spinal nerves to synapse in the **nucleus dorsalis**

Table 10.4 ● Ascending sensory pathways (subconscious).

Sensation	Sensory receptor	Location of cell body of first order neuron	Location of cell body of second order neuron	Pathway	Decussation of pathway (ipsilateral/contralateral)	
Pain and thermal sense from the body	A δ and C fibers	Dorsal root ganglion	Dorsal horn	Spinoreticular	Anterior white commissure	
				Spinotectal		
				Spinomesencephalic		
				Spinohypothalamic		
Two-point discriminative (fine) touch, tactile sensation, vibratory sense	Touch and pressure receptors	Dorsal root ganglion	Dorsal horn	Anterior spinocerebellar	Decussates in anterior white commissure and decussates again within cerebellum	
Proprioceptive sense from muscles and joints of the body, limb position sense	Muscle stretch receptors, Golgi tendon organs	Dorsal root ganglion	Dorsal horn (Clark's column) C8–L2,3	Posterior spinocerebellar	Ipsilateral	
			Dorsal root ganglion	Accessory cuneate nucleus	Cuneocerebellar	Ipsilateral
			Dorsal root ganglion	Dorsal horn	Rostral spinocerebellar	Ipsilateral

Table 10.5 ● Functions of the ascending sensory tracts to the cerebellum (subconscious).

Tract	Location of first order neuron cell body	Location of second order neuron cell body	Termination	Function
Dorsal (posterior) spinocerebellar	Dorsal root ganglion	Dorsal horn (Clark's column) C8–L2,3	Ipsilateral cerebellar vermis	Relays proprioceptive input from the ipsilateral trunk and lower limb Coordination of movements of the lower limb muscles Posture maintenance
Cuneocerebellar	Dorsal root ganglion	Accessory cuneate nucleus	Ipsilateral anterior lobe of the cerebellum	Relays proprioceptive information from the ipsilateral neck and upper limb Movement of head and upper limb
Ventral (anterior) spinocerebellar	Dorsal root ganglion	Dorsal horn	Ipsilateral cerebellar vermis	Relays proprioceptive input from the ipsilateral trunk and lower limb Coordination of movements of lower limb muscles Posture maintenance
Rostral spinocerebellar	Dorsal root ganglion	Dorsal horn	Cerebellum	Relays proprioceptive input primarily from the ipsilateral head and upper limb Movement of head and upper limb

Table 10.4 ● Continued.

Location of pathway in spinal cord	Pathway (second order neuron) termination	Location of cell body of third order neuron	Termination of third order neuron	Conscious/subconscious	Function(s)
Lateral funiculus	Reticular formation	Multiple synapses in brainstem reticular formation; fibers terminate in the intralaminar nuclei of the thalamus	Anterior cingulate cortex, anterior insular cortex	Subconscious	Relays pain and thermal sense from the body; input functions in arousal of the organism in response to pain
	Superior colliculus	–	–	Subconscious	Mediates reflex movement of the head, eyes, and upper trunk in direction of the stimulus
	Periaqueductal gray matter and raphe nucleus magnus	–	–	Subconscious	Involved in pain modulation
	Hypothalamus	–	–	Subconscious	Functions in the autonomic, reflex, and emotional aspects of pain
Lateral funiculus	Cerebellar vermis	–	–	Subconscious	Mediates coordination of muscle activity of the trunk and lower limb
Lateral funiculus	Cerebellar vermis	–	–	Subconscious	Relays proprioceptive information to the cerebellum, and functions in the coordination of movement of the lower limb and posture maintenance
–	Anterior lobe of the cerebellum	–	–	Subconscious	Neck and upper limb equivalent of the dorsal spinocerebellar tract
Lateral funiculus	Cerebellum	–	–	Subconscious	Mediates proprioception from the head and upper limb

(Clark’s column, lamina VII of spinal cord levels C8 to L2,3) at their level of entry. Sensory information transmitted by spinal nerves entering at the sacral and lower lumbar spinal cord levels (below Clark’s column) is relayed to the caudal extent of the nucleus dorsalis (L2,3) by ascending in the fasciculus gracilis.

Clark’s column houses the cell bodies of **second order neurons** whose axons form the **dorsal spinocerebellar tract**, which ascends ipsilaterally in the lateral funiculus of the spinal cord. When this tract reaches the brainstem it joins the restiform body (of the inferior cerebellar peduncle), and then passes (as “mossy fibers”) into the vermis of the cerebellum. The dorsal spinocerebellar tract relays proprioceptive information directly to the cerebellum where this information is processed; it plays an important role in the coordination of movements of individual lower limb muscles and in the maintenance of posture.

Cuneocerebellar tract

Proprioceptive sensory information from the neck, upper limb, and upper half of the trunk enters at spinal cord segments C2 to T5

Proprioceptive sensory information from the neck, upper limb, and upper half of the trunk enters at spinal cord segments C2 to T5. The

central processes of the pseudounipolar first order neurons ascend in the fasciculus cuneatus and terminate in the external (accessory) cuneate nucleus—the nucleus dorsalis of Clark homologue at cervical levels above C8 (Fig. 10.19A; Table 10.5).

The axons of the **second order neurons**, whose cell bodies are housed in the **accessory cuneate nucleus**, form the **cuneocerebellar tract**. This tract is referred to as the neck and upper limb counterpart of the dorsal spinocerebellar tract. Fibers of the cuneocerebellar tract join the restiform body (of the inferior cerebellar peduncle) and then enter the anterior lobe of the cerebellum ipsilaterally. Information carried by the cuneocerebellar tract plays a role in movements of the head and upper limbs.

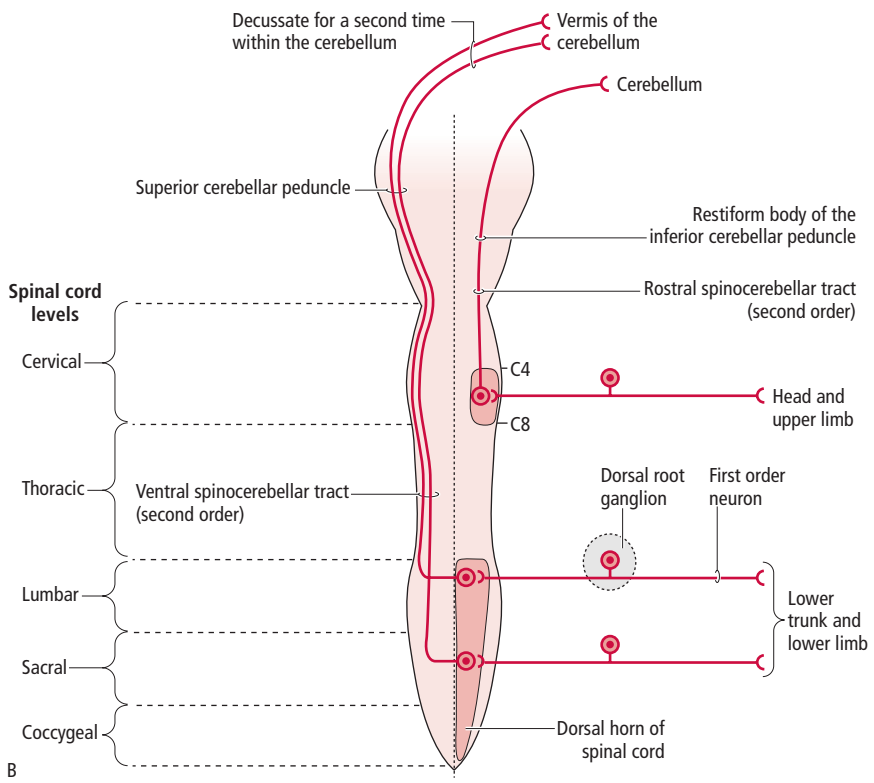
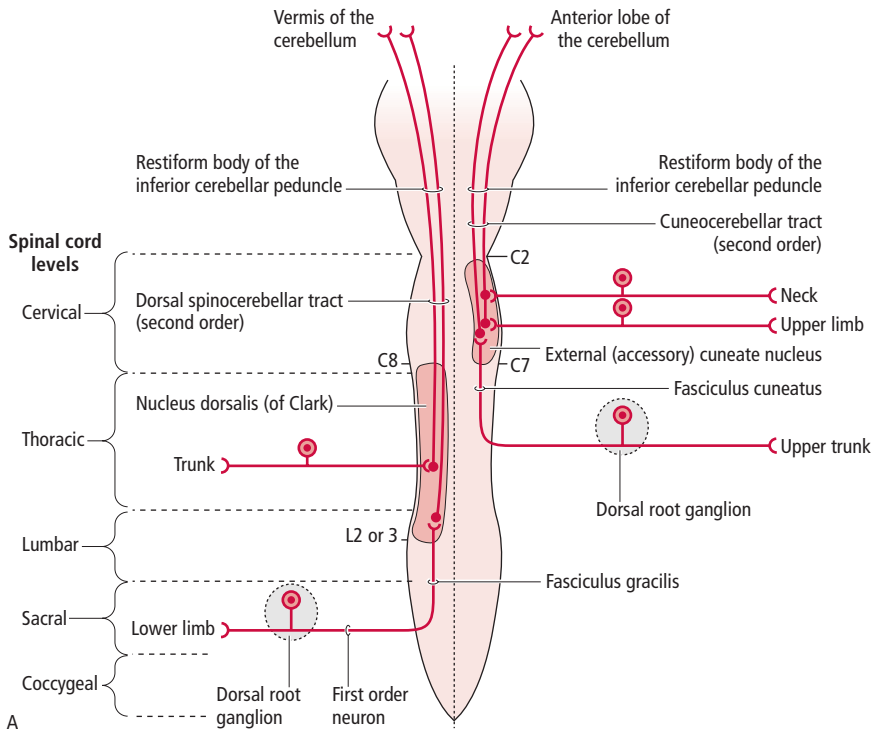


Figure 10.19 ● (A) Two of the ascending sensory pathways to the cerebellum: the dorsal spinocerebellar tract transmitting sensory information from the lower limb and trunk, and the cuneocerebellar tract transmitting sensory information from the neck, upper limb, and upper trunk to the cerebellum. (B) Two of the ascending sensory pathways to the cerebellum: the ventral spinocerebellar tract transmitting sensory information from the lower trunk and lower limb, and the rostral spinocerebellar tract transmitting sensory information from the head and upper limb to the cerebellum.

Ventral (anterior) spinocerebellar tract

The ventral (anterior) spinocerebellar tract relays proprioceptive information from the muscle spindles and GTOs of the trunk and lower limb

The ventral (anterior) spinocerebellar tract relays proprioceptive information from the muscle spindles and GTOs of the trunk and

lower limb. It functions in the coordination of movement of the lower limb, and maintenance of posture (Fig. 10.19B; Table 10.5).

First order neurons (pseudounipolar neurons) transmit sensory input to laminae V–VII of the lumbar, sacral, and coccygeal spinal cord levels, where they terminate and synapse with second order neurons.

The axons of these **second order neurons**, known as spinal border cells, form the **ventral (anterior) spinocerebellar tract**, which decussates in the anterior white commissure and ascends in the lateral funiculus of the spinal cord to the medulla. At pontine levels these fibers join the superior cerebellar peduncle to pass as “mossy fibers” into the vermis

of the cerebellum. These fibers then decussate again to their actual side of origin within the cerebellum.

Rostral spinocerebellar tract

Proprioceptive information from the head and upper limb is transmitted to C4–C8 spinal cord levels

Proprioceptive information from the head and upper limb is transmitted to C4–C8 spinal cord levels. The central processes of **first order neurons** synapse with second order neurons whose cell bodies reside in lamina VII of the dorsal horn. The fibers of the **second order neurons** form the primarily uncrossed **rostral spinocerebellar tract**, the head and upper limb counterpart of the ventral spinocerebellar tract. These fibers join the restiform body (of the inferior cerebellar peduncle) to enter the cerebellum. Additionally, some fibers pass into the cerebellum via the superior cerebellar peduncle (Fig. 10.19B; Table 10.5). This tract plays a role in movement of the head and upper limb.

These fibers join the restiform body (of the inferior cerebellar peduncle) to enter the cerebellum. Additionally, some fibers pass into the cerebellum via the superior cerebellar peduncle (Fig. 10.19B; Table 10.5). This tract plays a role in movement of the head and upper limb.

CLINICAL CONSIDERATIONS

Lesions involving peripheral nerves

The damage that occurs to a peripheral nerve, and the resulting sensory symptoms, differ depending on whether the damaged nerve carries sensory fibers and which fibers are involved in the lesion

The extent of damage that may occur to a peripheral nerve, and the sensory symptoms that will arise following a lesion, differ depending on whether the damaged nerve carries sensory fibers and which fibers are involved in the lesion. Diminished cutaneous sensation due to damage of the sensory fibers of a particular nerve is usually narrower than the range of distribution of the nerve, due to the overlapping areas of distribution of adjacent nerves.

Dorsal root and spinal nerve lesions

The sensory deficits that arise following a lesion to a dorsal root or to a spinal nerve are usually revealed in a segmental distribution

The sensory deficits that arise following a lesion to a dorsal root or to a spinal nerve are usually revealed in a segmental distribution (Fig. 10.20). Since peripheral nerves branch and extend their innervation into territories of adjacent nerves, a peripheral nerve lesion may include areas supplied by several adjacent spinal cord levels. Due to this innervation overlap, it is difficult to trace the sensory deficit to a single spinal nerve or dorsal root. Dorsal root irritation results in pain and **paresthesia** (G., “abnormal sensations”), such as tingling, itching, or pricking of the skin.

Spinal cord lesions

In order to be able to identify the site of a spinal cord lesion, one has to be familiar with the anatomical arrangement of the various ascending and descending tracts in the spinal cord. In general, the pathways relaying **pain, temperature, and nondiscriminative (crude) touch** from the body, ascend in the opposite side of origin, in the anterolateral aspect of the spinal cord. Pathways relaying **discriminative (fine) touch** and **proprioceptive** modalities ascend ipsilateral to the side of origin, in the dorsal white columns.

Brown-Séquard syndrome

Although spinal cord injuries are rarely limited to a particular tract, quadrant, or side of the spinal cord, the hemisection of the spinal cord is used for instructive purposes. One such example is the **Brown-Séquard syndrome** (Fig. 10.21).

When the **spinal cord is hemisected** (only the right or left half is severed), all of the tracts (both ascending and descending) coursing through the level of the lesion are severed, and the following will be observed.

- 1 The lower motoneurons ipsilateral to and at the level of the lesion will be damaged, leading to **ipsilateral lower motoneuron paralysis** at the level of the lesion.
- 2 Since the corticospinal tract (upper motoneurons) will be severed, the individual will exhibit an **ipsilateral loss of motor function** below the level of the lesion, followed by **spastic paralysis** (see Chapter 11).

For **sensory deficits** at or below the level of the lesion, the following will be observed.

- 1 Since the **anterolateral system** (which includes the spinothalamic, spinoreticular, spinomesencephalic, spinotectal, and spinohypothalamic fibers) has been severed, there will be a contralateral loss of:
 - **pain and temperature sensation** beginning one or two segments below the level of the lesion; and
 - **nondiscriminative (crude) touch sensation** beginning three to four segments below the level of the lesion.
- 2 Since the **dorsal column pathways** (**fasciculus gracilis** and **fasciculus cuneatus**) have been severed, there will be an ipsilateral loss of the following, below the level of the lesion:
 - **discriminative (fine) touch;**
 - **vibratory sensation;**

CLINICAL CONSIDERATIONS (continued)

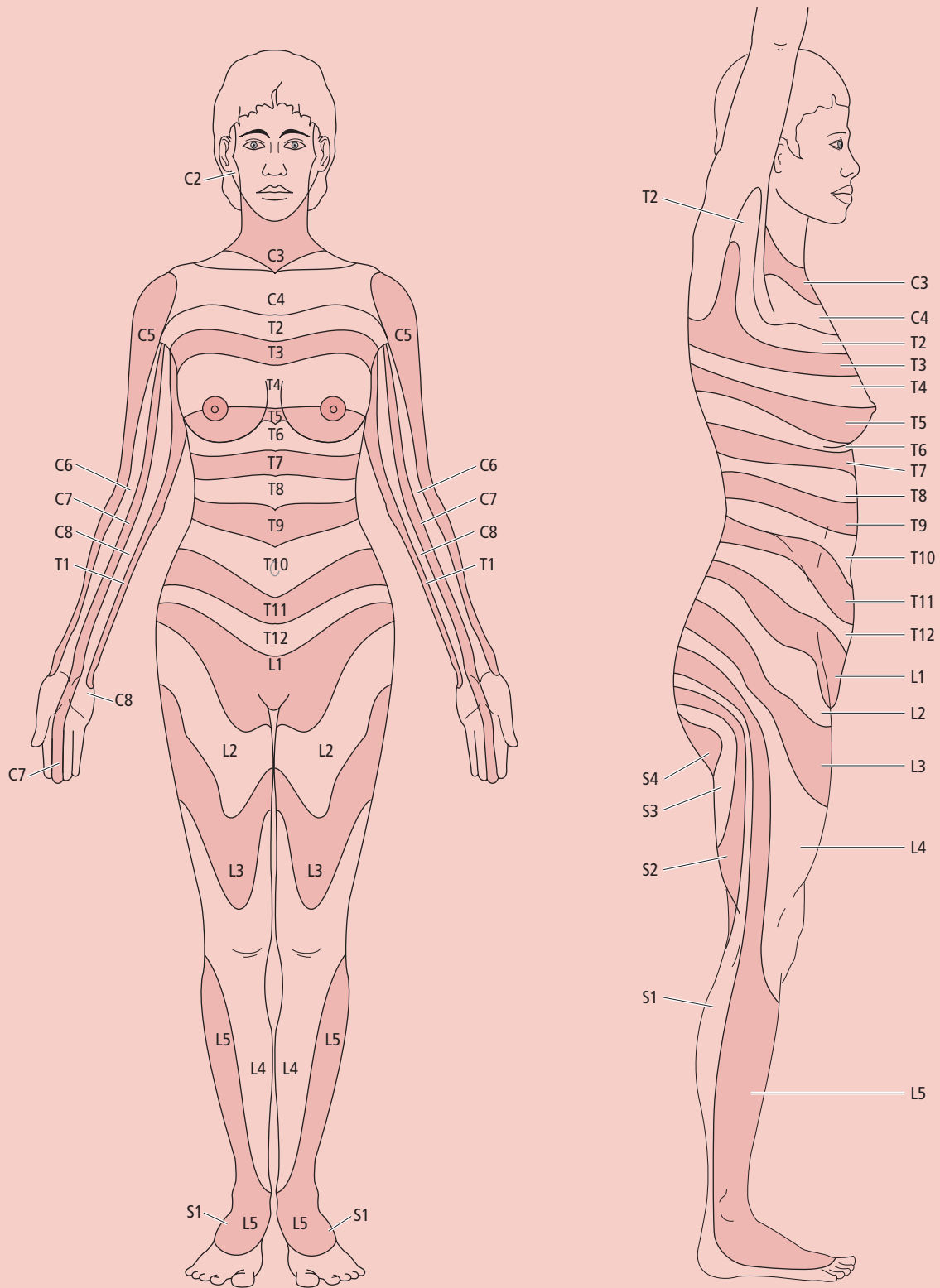


Figure 10.20 ● Dermatomes of the skin. Each striped area represents the skin innervated by a single dorsal root ganglion (on each side).

CLINICAL CONSIDERATIONS (continued)

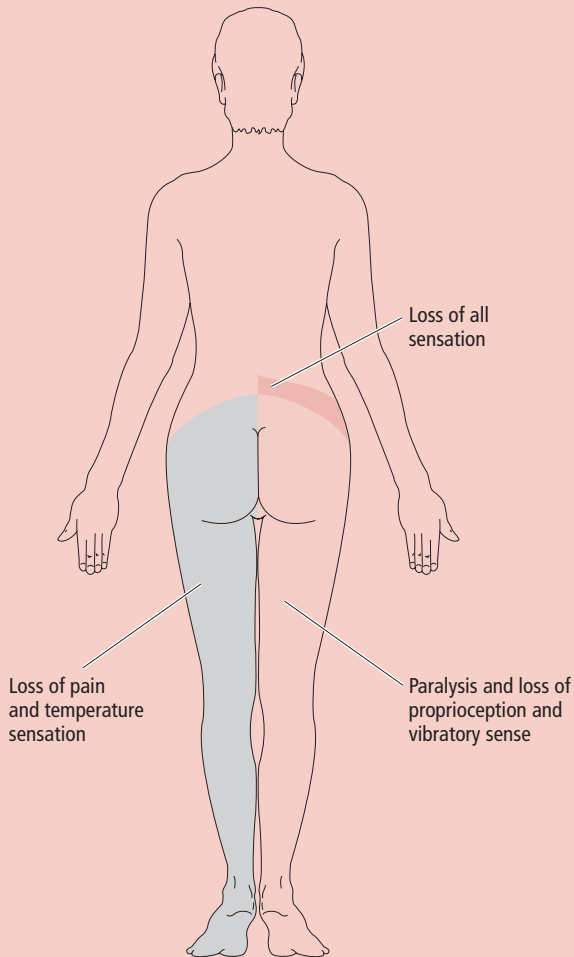


Figure 10.21 ● Brown-Séquard syndrome. The figure shows the deficits resulting following hemisection of the right side of the spinal cord at the level of T12.

- **proprioceptive (joint position) sensation:** an individual with this type of lesion will have coordination difficulties (**dorsal column sensory ataxia**); if the lesion involves the sensory innervation of the lower limbs the individual will have difficulty in maintaining his balance when his feet are closely approximated and when his eyes are closed (positive **Romberg sign**);
- **astereognosis (stereoaesthesia)** (G. astereognosis, “inability to know solids”): an individual with astereognosis is unable to identify the shape and form of a known object (such as a fork) following manual examination with the eyes closed, but can identify the object by sight; and
- **two-point discrimination:** the individual is unable to perceive simultaneous stimulation by a blunt instrument at two separate points on the skin as two distinct points of stimulation.

Since crude touch is carried by more than one ascending sensory pathway, ascending on *both* sides of the spinal cord, some touch sensation remains intact in individuals with Brown-Séquard syndrome. Furthermore, if *only* the

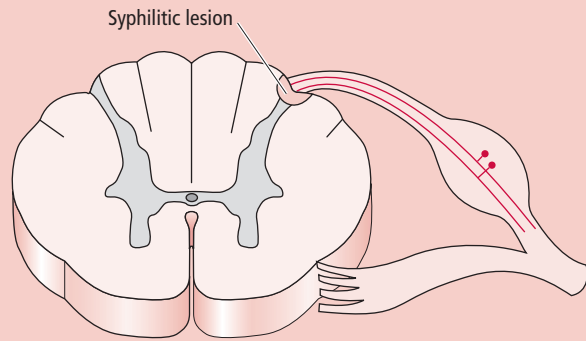


Figure 10.22 ● Location of a syphilitic lesion on the spinal cord.

dorsal right quadrant of the spinal cord is damaged, pain and temperature sensation will not be affected, whereas there will be a loss of discriminative (fine) touch and proprioceptive sensation, below the level of the lesion on the ipsilateral (right) side of the body.

Tabes dorsalis

Tabes dorsalis, a form of tertiary neurosyphilis, is a rare condition which is manifested during the second decade after an individual becomes infected with the microorganism causing syphilis

Tabes dorsalis, a form of tertiary neurosyphilis, is a rare condition which is manifested during the second decade after an individual becomes infected with the microorganism causing syphilis. This condition is characterized by sensory ataxia (G. ataxia, “without order”) resulting from impairment of two-point discrimination, vibratory sense, position sense, and kinesthesia. Individuals with this condition find it necessary to look at their lower limbs during walking. Additionally, they have difficulty standing up straight if their feet are closely approximated when their eyes are closed, or if they are standing in the dark (referred to as **Romberg’s sign**). There is also degeneration of the large-diameter, heavily myelinated fibers coursing in the medial division of the dorsal root; thus sensory information from the mechanoreceptors to the ascending sensory pathways is also affected (Fig. 10.22). Additionally, these individuals experience abnormal pain sensations.

Friedreich’s ataxia

Friedreich’s ataxia is a hereditary disorder that is manifested prior to, or during, puberty

Friedreich’s ataxia is a hereditary disorder that is manifested prior to, or during, puberty. In this condition, the **spinocerebellar tracts** as well as the **dorsal column pathways** degenerate and, consequently, produce an increasingly deteriorating ataxia.

Subacute combined degeneration

In **subacute combined degeneration** both the corticospinal tracts and the dorsal column pathways undergo degeneration

In **subacute combined degeneration**, as a result of vitamin B₁₂ deficiency, both the corticospinal tracts and the dorsal column pathways undergo degeneration. The deficits in the affected individual are characterized by muscle weakness as a result of the degeneration of the corticospinal (motor) tracts, and loss of vibratory sense, two-point discrimination, and proprioception as a result of the degeneration of the dorsal column pathways.

CLINICAL CONSIDERATIONS (*continued*)

Syringomyelia

Syringomyelia is a disease in which the central canal of the spinal cord, usually at the lower cervical or upper thoracic spinal cord levels, becomes enlarged

Syringomyelia (G. syrinx, "tube") is a disease in which the central canal of the spinal cord, usually at the lower cervical or upper thoracic spinal cord levels, becomes enlarged (although the enlargement of the central canal may extend cranially and/or caudally) (Fig. 10.23). The enlarging canal stretches and damages the surrounding nerve tissue. The tissue affected first is the anterior white commissure containing crossing fibers, followed by the damage to the anterior horn. This results in:

- 1 **Loss of pain and temperature sensation** from the skin of both shoulders and upper extremities due to the destruction of the second order neuron

decussating fibers that relay pain and temperature input. If the lesion involves only the cervical levels of the spinal cord, the anterior surface of the arm and forearm is not affected since it is innervated by T1 and T2.

- 2 **Weakness and atrophy** of the intrinsic muscles of the hands due to the degeneration of the motoneurons in the anterior horn of the spinal cord. If the disease progresses to include additional spinal cord levels and more nerve tissue surrounding the increasingly enlarged space, additional deficits will become apparent.

Vascular problems of the spinal cord

Anterior spinal artery syndrome

Occlusion of the anterior spinal artery, either by a thrombus or by compression, will obstruct blood flow to the ventral two-thirds of the spinal cord, and result in infarction

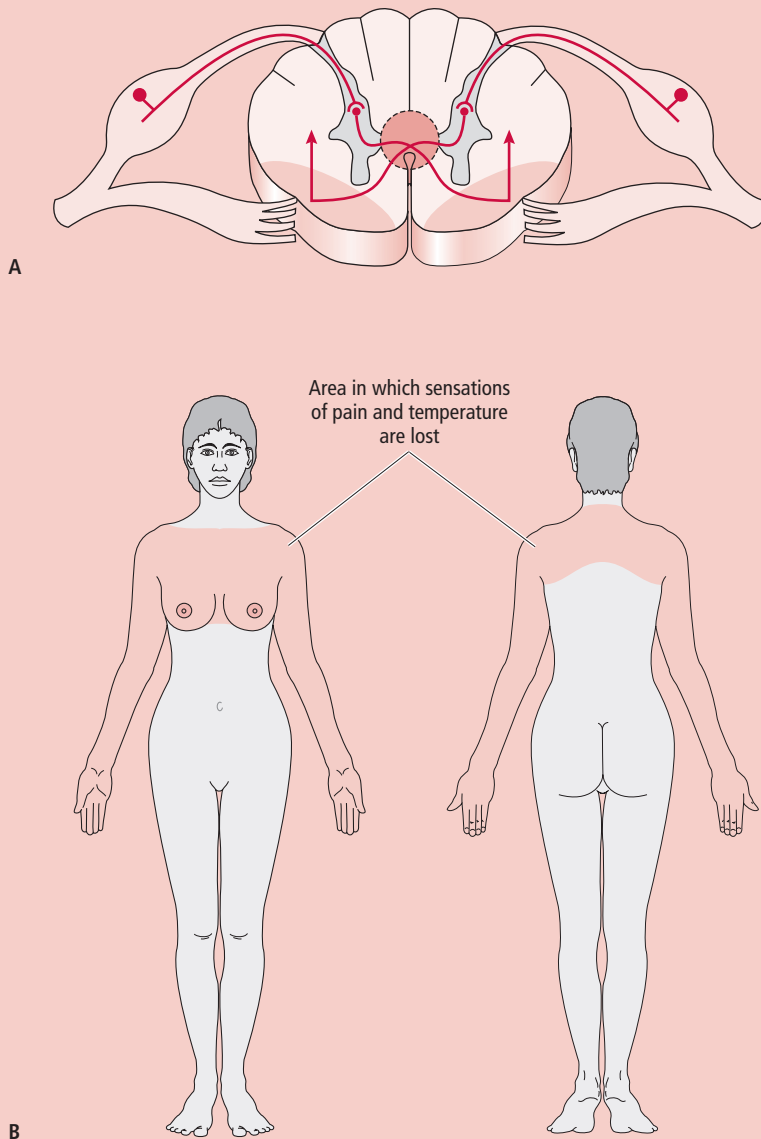


Figure 10.23 ● Syringomyelia. (A) Damage of decussating fibers of the pain and temperature pathway. (B) Skin area in which there is loss of pain and temperature sensation following the development of syringomyelia.

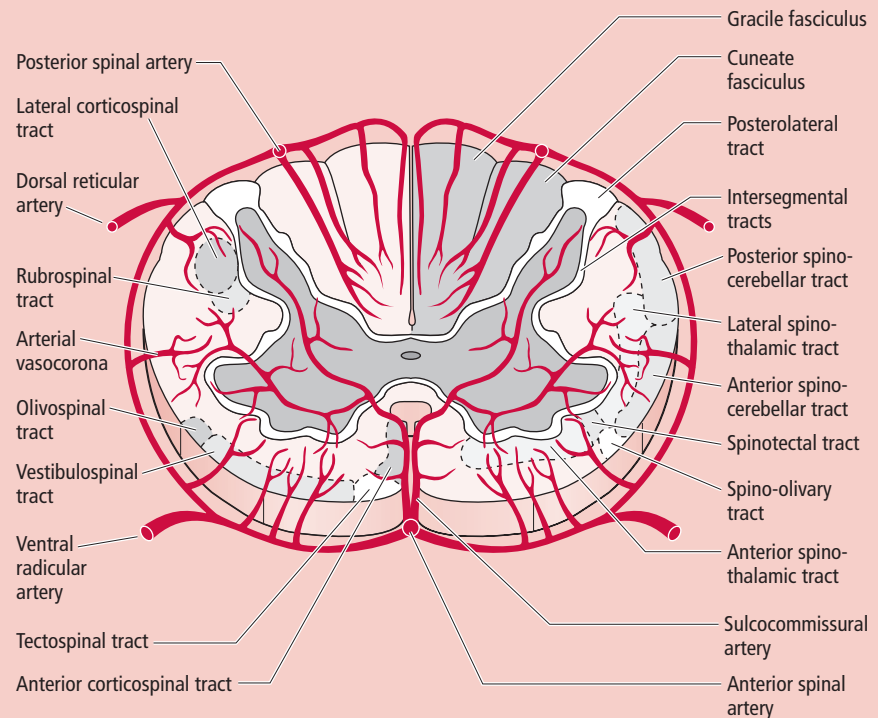
CLINICAL CONSIDERATIONS (*continued*)

Figure 10.24 ● Cross-section of the spinal cord and its arterial supply.

Occlusion of the anterior spinal artery, either by a thrombus or by compression, will obstruct blood flow to the ventral two-thirds of the spinal cord, and will result in infarction (Fig. 10.24). If the anterior spinal artery is occluded or compressed near the artery's origin in the medulla, structures located in the anterior aspect of the medulla, such as the pyramid and medial lemnisci, will be affected. Damage of the corticospinal fibers in the pyramid above its decussation will result in contralateral hemiparesis. Damage of the medial lemniscus will result in loss of proprioception and vibratory sense from the opposite side of the body.

If occlusion or compression of the anterior spinal artery occurs at spinal levels, it will result in damage of the corticospinal tract fibers and the anterior horns of the spinal cord. This is characterized by motor function deficits ipsilateral to, and below, the level of the lesion. Since the dorsal column pathways are not affected by occlusion of the anterior spinal artery at spinal levels, discriminatory (fine) touch and position sense remain intact.

Posterior spinal artery occlusion or compression

The two posterior spinal arteries supply the dorsal one-third of the spinal cord; if either is occluded or compressed, it results in infarction of the dorsal white columns and the ALS

The two posterior spinal arteries supply the dorsal one-third of the spinal cord (Fig. 10.24). If one or both of the posterior spinal arteries is/are occluded or compressed, it results in infarction of the dorsal white columns and the ALS. If only one of the posterior spinal arteries is occluded, or compressed, it will result in loss of discriminatory (fine) touch and proprioceptive sensation, ipsilaterally, and loss of pain and temperature sensation, contralaterally, below the level of the lesion. If infarction occurs at caudal medullary levels, near the level of the vessels' origin, the dorsal white columns and their respective nuclei

will be damaged. Since the spinothalamic tract is located in the anterolateral aspect of the caudal medulla, it is not affected.

Central or thalamic pain

A lesion of the spinothalamic tract and its nucleus of termination may cause agonizing pain or other unusual sensations

Lesions involving the spinothalamic tract and its nucleus of termination, the ventral posterior lateral nucleus of the thalamus, may initially cause diminished or complete loss of touch, pressure, pain, or temperature sensation, or proprioception from the contralateral side of the body. Spontaneous, inexplicable, agonizing pain and other unusual sensations in the anesthetic parts may follow. This condition is known as central pain (thalamic pain, thalamic syndrome).

Lesions involving the somatosensory cortex

Isolated lesions in the **postcentral gyrus** are uncommon. However, since the postcentral gyrus is supplied by branches of the middle cerebral artery, a vessel which often becomes occluded, this region of the brain may become infarcted. A lesion to the primary somatosensory cortex will result in contralateral loss of:

- 1 **Two-point discrimination.**
- 2 **Graphesthesia**, the ability to recognize letters or numbers as they are stroked on the skin.
- 3 **Stereognosis**, the ability to identify a known object following tactile examination without looking.
- 4 **Vibratory sense.**
- 5 **Position sense.**

CLINICAL CONSIDERATIONS (*continued*)

Furthermore, although the individual has a minimal impairment of **pain**, **temperature**, and **touch sensation**, he is unable to *localize* the stimulus. Since pain perception is not only processed in the **somatosensory cortex**, but also in the **anterior cingulate** and **anterior insular cortices**, pain sensation persists following a lesion to the somatosensory cortex as a result of these additional cortical representations of pain.

In recent years, a bilateral **cingulotomy** (transection of the anterior part of the cingulum bundle) has served as an effective treatment in relieving the emotional, agonizing reaction to pain. An isolated lesion in the secondary somatosensory cortex (S-II) results in minimal sensory loss, but since S-II has an important function in memory of somatosensory information and sensory integration, these functions are impaired.

Referred pain

Pain originating in a visceral structure may be referred to and felt in a somatic structure

The actual origin of visceral pain is imprecisely localized. Although pain may originate deep within a visceral structure, such as the heart, the pain may be “referred to,” and felt, in another, distant somatic structure such as the left upper limb. Although several explanations have been proposed for this phenomenon, the following two have the most prominence in the field of neuroscience.

Convergence–projection theory of visceral pain

The **convergence–projection theory** of visceral pain, suggests that the central processes of pseudounipolar sensory, general visceral afferent (GVA) neurons supplying visceral structures and the central processes of general somatic afferent (GSA) neurons from a somatic structure, such as the upper limb, enter and terminate at the *same spinal cord level*. Here they converge on and synapse with the same interneurons and/or second order neurons (viscerosomatic neurons) of the ascending pain pathways in the dorsal horn, and the intermediate gray matter. Nociceptive information is transmitted by these GSA pathways to higher brain centers.

Concept of referred pain

Second order GSA projection neurons are continuously being activated by GVA first order neurons, thereby lowering the threshold of stimulation of the second order neurons. Consequently, nociceptive sensory information is relayed by the neurons of the GSA pathway to higher brain centers. Thus, GVA nociceptive input is transmitted via the spinoreticular fibers to the reticular formation, the thalamus, and the hypothalamus. The nociceptive signal is subsequently relayed to the region of the somesthetic cortex that normally receives somatic information from other areas, such as the upper limb, and the brain interprets it as if the pain were coming from that somatic structure (upper limb). Therefore, it is the area(s) of the cerebral cortex, in this case the somatosensory cortex, wherein the signals *terminate*, and not the stimulus, the receptor, or the information, that establishes the localization of the sensation.

Phantom limb pain

Individuals who have had a limb amputated may experience pain or tingling sensations that feel as if they were coming from the amputated limb, just as if that limb were still present

A curious phenomenon has been reported by individuals who have had a limb amputated. These individuals experience pain or tingling sensations that feel as if they were coming from the amputated limb, just as if that limb were still present. Although the mechanism of phantom limb pain is not understood, the following two possible explanations are offered.

If a sensory pathway is activated anywhere along its course, nerve impulses are generated that travel to the CNS where they initiate neural activity. This neural activity ultimately “creates” sensations that feel as though they originated in the nonexistent limb.

Another possibility is that since there is no touch, pressure, or proprioceptive information transmitted to the CNS from the peripheral processes of the sensory neurons that initially innervated the amputated limb, there are no impulses from touch fibers to attenuate the relaying of nociceptive impulses to the nociceptive pathways, enhancing nociceptive transmission and pain sensation (see the gate control theory of pain, below). Since nociception is not as localized, cortical areas corresponding to the phantom limb will be activated.

MODULATION OF NOCICEPTION

The CNS can prevent and/or suppress the flow of some of the incoming nociceptive signals from peripheral structures

Although the CNS is constantly flooded with sensory information, it can prevent and/or suppress the flow of some of the incoming nociceptive signals at the local circuitry level of the spinal cord dorsal horn (and spinal trigeminal nucleus of the brainstem). The CNS can also do this at the level of the descending opioid and nonopioid analgesia-producing pathways that originate in the brainstem, and terminate at the relay sensory nuclei of the ascending sensory systems.

Gate control theory of pain

Nociceptive signals from the periphery are filtered by modulation in the substantia gelatinosa of the dorsal horn

Rubbing a painful area (activation of touch A δ /A β fibers) reduces the sensation

of pain. It has been proposed that the **substantia gelatinosa (lamina II)** of the dorsal horn gray matter is the site where pain is filtered by modulation of the sensory nociceptive input to the spinothalamic pain and temperature pathway neurons. The theory proposed to explain this phenomenon, known as the **gate control theory of pain**, suggests that the neural circuitry of the substantia gelatinosa (SG) functions as follows (Fig. 10.25).

The activity of nociceptive unmyelinated C fibers and thinly myelinated A δ fibers terminating in the SG transmit nociceptive impulses by: (i) inhibiting the SG inhibitory interneuron; and (ii) simultaneously activating the second order spinothalamic tract neuron that projects to the thalamus, “keeping the gate open.”

The touch A δ /A β myelinated fibers activate the inhibitory interneuron as well as the second order neuron. However, the inhibitory interneuron, via presynaptic inhibition of the C/A δ and A δ /A β fibers, prevents impulses from reaching

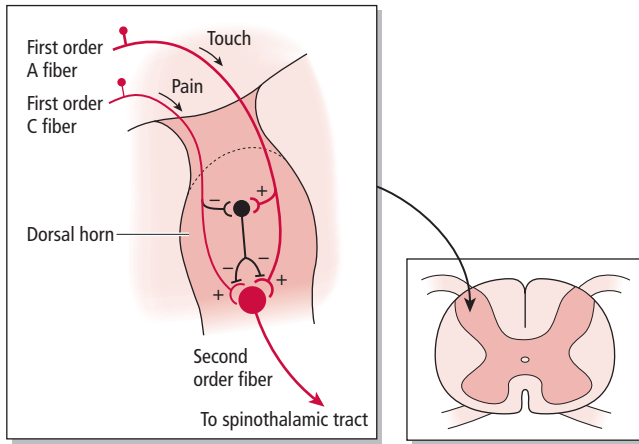


Figure 10.25 • Gate control theory of pain. Stimulation of the C fibers transmitting nociception keeps the gate to higher brain centers open, whereas stimulation of the large-diameter A fiber closes the gate. (Modified from Heimart, L (1995) *The Human Brain*. Springer-Verlag, New York; fig. 9.2.)

the second order spinothalamic neuron. When someone injures his fingers, for example, he usually rubs the painful area. The rubbing probably stimulates the $A\delta/A\beta$ fibers, which in turn—via the inhibitory interneuron—inhibit the transmission of some of the nociceptive impulses to higher brain centers, providing some relief from pain.

Descending analgesia-producing pathways

Descending analgesia-producing pathways arise from the brainstem and terminate in the spinal cord

Although it was known for many years that opiates, a group of drugs derived from opium (e.g., morphine) provide powerful relief from pain, their mode of action was not understood. It is now known that the opiates bind to “opiate receptors” on specific nerve cells residing in certain areas of the CNS. It was then speculated that, for the nervous system to have “opiate receptors,” it must synthesize its own endogenous, opiate-like substances that bind to the “opiate receptors,” which probably modulate afferent nociceptive transmission. Three groups of related endogenous opioid peptides have been identified: **enkephalin** (G. enkephalin, “in the head”), **beta-endorphin** (“morphine within”), and **dynorphin** (dynamo + morphine) all of which are known to bind to the same receptors as the opioid drugs.

During a stressful or emotional experience, regions associated with the processing of emotions—namely the telencephalon (frontal cortex), the diencephalon (hypothalamus), and the limbic system—project to and stimulate the enkephalin-releasing neurons of the **periaqueductal gray matter** and other nearby regions of the midbrain. The axons of these enkephalin-releasing neurons form excitatory synapses primarily with the serotonin-releasing neurons of the **raphe nucleus magnus** and the **nucleus gigantocellularis** of the rostral **medullary reticular formation**. Since these neurons release serotonin, they are said to form the **serotonergic-opioid peptide analgesic system**, which modulates nociception. In addition to the serotonergicopioid

peptide analgesic system, there is a **norepinephrine** (adrenergic, nonopioid) **analgesic system** that arises from the **dorsolateral pontine reticular formation** and terminates in the SG of the spinal cord, and also functions in modulating nociception (see discussion below).

Serotonin-releasing neurons

The axons of the **serotonin-releasing neurons** from the raphe nucleus magnus and the nucleus gigantocellularis descend bilaterally in the lateral funiculus of all spinal cord levels to terminate in the SG of the dorsal horn. Here they form excitatory synapses with the inhibitory interneurons, which release the opioid peptides, enkephalin or dynorphin. These interneurons establish axoaxonic synapses with the central processes of the $A\delta$ and C first order nociceptive neurons.

The modulation of nociception occurs in the following fashion. Upon stimulation of the free nerve ending of a pain fiber, the central process of this first order neuron releases substance P, a neurotransmitter believed to function in the transmission of nociceptive information, that excites the second order nociceptive relay neurons in the dorsal horn. If the serotonin-releasing neurons excite the inhibitory interneurons of the SG, these interneurons in turn inhibit the central processes of the first order neurons. Since this inhibition occurs before the impulse reaches the synapse, it is referred to as **presynaptic inhibition** (Fig. 10.26). Thus these nociceptive incoming impulses are filtered by being suppressed at their first relay station in the spinal cord, by the SG inhibitory interneurons releasing enkephalin or dynorphin. This inhibition occurs because the central processes of these first order neurons possess receptors for enkephalin and dynorphin (opioid receptors) in their axolemma.

There is additional evidence suggesting that there are indeed opioid receptors in the axolemma of the central terminals of the first order nociceptive, substance P-releasing neurons terminating in the SG. This evidence is gathered from reports that naloxone, an opioid antagonist, selectively prevents the blocking of substance P release by the central processes of the first order neurons.

Norepinephrine-releasing neurons

Another brainstem region, the **dorsolateral pontine reticular formation** (Fig. 10.27), is the site of origin of a norepinephrine (adrenergic, nonopioid) analgesic pathway that descends in the dorsolateral funiculus of the spinal cord to synapse in the SG (lamina II). Fibers of this pathway make synaptic contact with inhibitory interneurons of the SG (that may release gamma aminobutyric acid (GABA)), thus ultimately leading to the inhibition of the second order projection neurons that reside in lamina V of the dorsal horn of the nociceptive pathway. Unlike the descending opioid analgesic pathways, the effects of the adrenergic (norepinephrine-releasing) pathway are not blocked by naloxone.

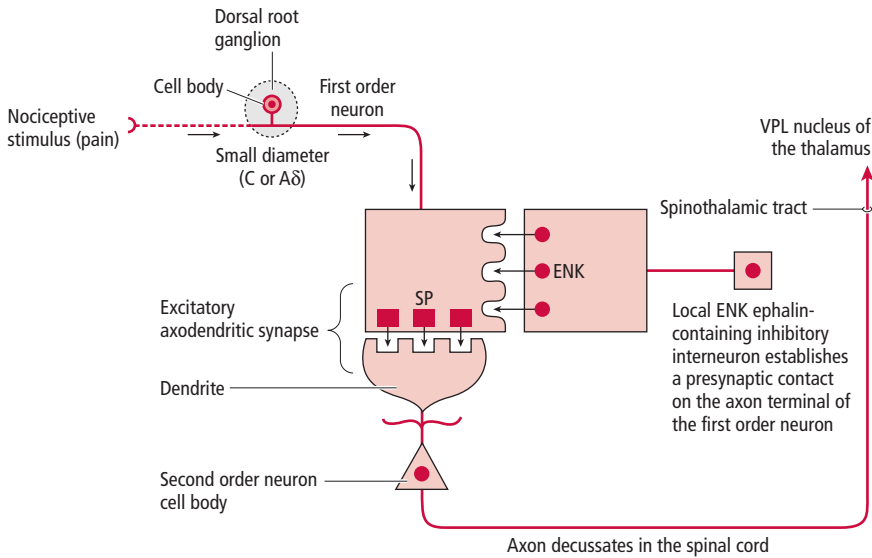


Figure 10.26 ● Opiate-induced suppression of substance P (SP) release in the substantia gelatinosa of the spinal cord dorsal horn. Note the substance P release by the central process of the first order neuron where it synapses with a second order projection neuron of the spinothalamic tract. The local enkephalin-releasing inhibitory interneuron establishes a presynaptic contact on the axon terminal of the first order neuron inhibiting the release of substance P. ENK, enkephalin; VPL, ventral posterior lateral.

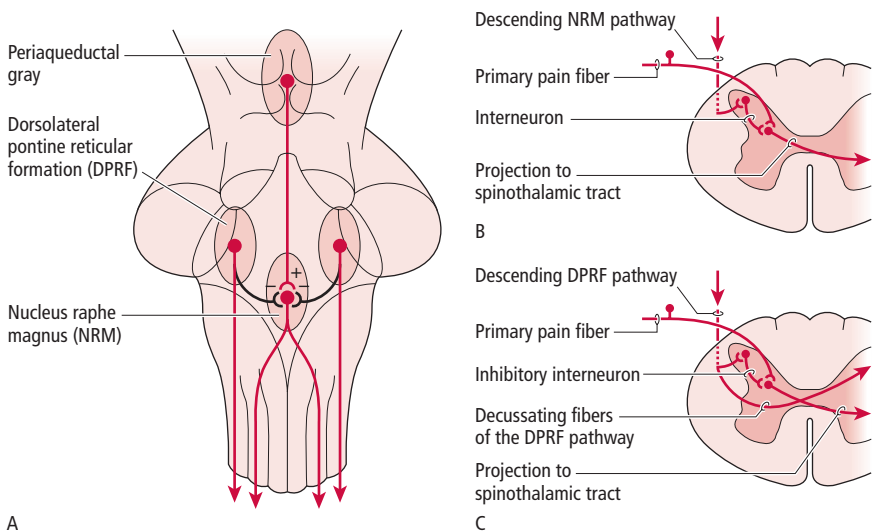


Figure 10.27 ● The descending analgesic pathways. (A) The midbrain periaqueductal gray matter contains enkephalergic neurons whose axons descend to terminate in the nucleus raphe magnus (NRM) containing serotonergic neurons. These neurons in turn descend bilaterally to terminate in the dorsal horn of the spinal cord. (B) Descending serotonergic fibers arising from the NRM terminate on enkephalergic and dynorphin-containing interneurons in the substantia gelatinosa of the spinal cord. The interneurons inhibit transmission of nociception via presynaptic inhibition of the first order afferent neurons. (C) Descending adrenergic fibers arising from the dorsolateral pontine reticular formation (DPRF) terminate bilaterally on inhibitory interneurons of the substantia gelatinosa of the spinal cord. The interneurons inhibit the second order projection neurons of the spinothalamic tract. (Modified from Burt, AM (1993) *Textbook of Neuroanatomy*. WB Saunders, Philadelphia; fig. 10.25.)

NEUROPLASTICITY

Plastic alterations in neural structures may be induced by a noxious insult that may enhance the magnitude of nociception

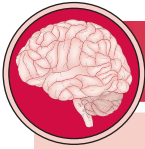Classically, the nociceptive system has been thought of as a sensory system that transmits pain signals from peripheral structures to the spinal cord, brainstem, and higher brain centers. Afferent nociceptive input may be modulated at the dorsal horn level,

filtering some of the pain signals, preventing them from being transmitted to higher brain centers.

Recent studies indicate that not only modulation but also “plastic” alterations may be induced in peripheral nerve terminals, the spinal cord, and the brain in response to a noxious insult. These modifications may enhance the magnitude of nociception and may be a factor in the development of pain that may last only days, or may become persistent and last for months, years, or may become permanent.

SYNONYMS AND EPONYMS OF THE ASCENDING SENSORY PATHWAYS

Name of structure or term	Synonym(s)/eponym(s)	Name of structure or term	Synonym(s)/eponym(s)
Astereognosis	Stereoanesthesia	Lamina VII of the dorsal horn of the spinal cord	Nucleus dorsalis
Corpuscle of Ruffini	Ruffini's end organs		Clark's nucleus
Cuneocerebellar tract	Cuneatocerebellar tract		Clark's column
Discriminative tactile sensation	Discriminative touch sensation	Merkel's disc	Merkel's corpuscle
	Fine touch sensation	Muscle spindle	Neuromuscular spindle
Dorsal column nuclei	Nucleus gracilis (NG) and nucleus cuneatus (NC)	Nondiscriminative touch sensation	Crude touch sensation
Dorsolateral fasciculus	Tract of Lissauer	Postcentral gyrus	Primary sensory cortex (S-I)
	Lissauer's tract		Primary somatosensory cortex
Dynamic proprioception	Kinesthetic sense		Primary somesthetic cortex
External cuneate nucleus	Accessory cuneate nucleus	Projection neuron	Brodmann's areas 3, 1, and 2
Extrafusal muscle fibers	Skeletal muscle fibers (of gross muscle)	Pseudounipolar neuron	Second order neuron
			Primary sensory neuron
Functional component	Functional modality		First order neuron
Golgi tendon organ (GTO)	Neurotendinous spindle	Rapidly adapting receptors	Afferent neuron
Hairless skin	Glabrous skin	Secondary somatosensory cortex (S-II)	Phasic receptors
Interneuron	Internuncial neuron		Secondary somesthetic cortex
Intrafusal muscle fibers	Skeletal muscle fibers of muscle spindles	Slowly adapting receptors	Brodmann's area 43
		Spinothalamic tract	Tonic receptors
Lamina I of the dorsal horn of the spinal cord	Posteromarginal nucleus or zone		Neospinothalamic pathway
Lamina II of the dorsal horn of the spinal cord	Substantia gelatinosa (SG)	Static proprioception	Direct pathway of the anterolateral system (ALS)
Lamina V of the dorsal horn of the spinal cord	Reticular nucleus	Thalamic pain	Static position sense
		Thermal receptor	Thalamic syndrome
			Temperature receptor



FOLLOW-UP TO CLINICAL CASE

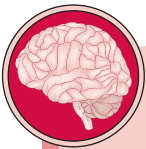This woman has a primarily sensory disturbance that involves the distal extremities bilaterally. Severe sensory disturbance, even in the absence of motor deficits or cerebellar abnormality, often leads to gait ataxia or incoordination of the hands depending on whether the feet and/or hands are involved. Therefore, the cerebellum is not necessarily involved, but it may be a good idea to check it with imaging.

The first thing to determine in this case is whether the sensory dysfunction is from pathology in the CNS or the peripheral nervous system (PNS) (e.g. peripheral neuropathy). The PNS can be evaluated by nerve conduction studies, which reveal how well an electric impulse is conducted by a peripheral nerve. The CNS and the nerve roots can be evaluated by radiologic imaging, particularly MRI. In the present case, nerve conduction studies were essentially normal. Other tests indicate normal nerve roots. These tests indicate that the CNS should be evaluated closely. The brisk reflexes in the legs, particularly at the ankles, also indicate peripheral neuropathy is unlikely. MRI of the brain and spinal cord is unrevealing.

Laboratory tests to check for a metabolic, or possibly a genetic, cause of pathology to the sensory pathways in the CNS are indicated.

Laboratory tests indicate that this patient has **subacute combined degeneration**, secondary to vitamin B₁₂ deficiency. Vitamin B₁₂ is a cofactor in enzymatic reactions that are critical for DNA synthesis and neurologic function. Deficiency leads to degeneration of white matter in general, but the posterior columns in the spinal cord tend to be affected early and prominently. The reason for this predilection is not clear. Motor fibers of the corticospinal tract in the spinal cord are also affected relatively early and can lead to bilateral leg weakness. Dementia from degeneration in the brain and visual disturbance from optic nerve involvement may also occur.

Pernicious anemia is an autoimmune disease of gastric parietal cells that ultimately leads to decreased absorption of vitamin B₁₂ from the small intestine. Treatment with vitamin B₁₂ supplementation is very effective if the disorder is caught early.



5 Is there a peripheral nervous system neuropathy?

6 If this patient's disorder remains undiagnosed and untreated, what other systems are likely to be affected?

QUESTIONS TO PONDER

1. Why is it that an individual responds to a fly walking on the wrist of the right hand, but not to the watch on the left wrist?
2. How do muscle spindles detect a change in muscle length (resulting from stretch or contraction) irrespective of muscle length at the onset of muscle activity?
3. In a simple stretch reflex, what indicates the load placed on a muscle?
4. What is the response of the muscle spindles and Golgi tendon organs during slight stretching and then during further stretching of a muscle?
5. Why does an individual with a lesion in the primary somatosensory cortex still perceive pain?
6. Why is it that when an individual is experiencing a heart attack he feels pain not only in the chest area, but also in the left shoulder and upper limb?